

## Grand Rounds

# A 51-year-old woman with binocular diplopia and unilateral ptosis

Landon J. Rohowetz, BS<sup>a</sup>, and Anjolie K. Quick, MD<sup>b</sup>

Author affiliations: <sup>a</sup>University of Missouri – Kansas City School of Medicine, Kansas City, Missouri;

<sup>b</sup>Department of Ophthalmology, University of Kansas School of Medicine, Prairie Village, Kansas

## History

A 51-year-old woman with a history of acute myeloid leukemia (AML) in remission and no past ocular history presented emergently at the University of Kansas Hospital with binocular diplopia and right-sided ptosis of 3 days' duration. The patient also complained of fatigue. She originally attributed her symptoms to allergies, stating that she had also recently experienced mild right-sided eye discharge and sinus pressure. Past medical history was significant for mild hypertension and AML with myelodysplasia-related features that was treated about 6 months prior with haploidentical peripheral stem-cell transplantation. The patient was a former smoker (40 pack-years) and had a family history of glaucoma (sister). She had recently finished a regimen of fluconazole for prophylaxis after stem-cell transplantation and was also taking acyclovir, letermovir, dapsone, and tacrolimus.

## Examination

Best-corrected near visual acuity with +2.50 reading glasses was 20/30 in the right eye and 20/30 in the left eye. In room light, the right pupil measured 6 mm and was 1+ reactive; the left pupil, 4 mm and 3+ reactive. Confrontation visual field testing was unremarkable. There was no relative afferent pupillary defect. Motility in the right eye was -4 to adduction and supraduction and -3 to infraduction (Figure 1). Left eye motility was full. The right eye was exo- and hypotropic, and there was complete ptosis, with no observable corneal light reflex. (Given the inpatient setting and the acuteness of the patient's condition, prism correction was not measured at this time but was deferred until outpatient follow-up.) The left eye was without ptosis. No exophthalmos nor enophthalmos was apparent. The rest of the

examination, including fundus and the remainder of the cranial nerve examination, was unremarkable.

## Ancillary Testing

A complete blood count revealed anemia, with a hemoglobin concentration of 11 g/dL, but platelet and white blood cell counts were within normal limits. Electrolytes and coagulation studies were also within normal limits. With findings consistent with oculomotor nerve palsy, the patient was managed with the intent to urgently rule out aneurysm. Immediate computed tomography angiogram (CTA) of the head and neck was ordered, followed by magnetic resonance imaging (MRI), with and without contrast, of the head and orbits. CTA was unremarkable. T2-weighted MRI revealed mild right-sided proptosis and slightly increased cerebrospinal fluid (CSF) signal surrounding the right optic nerve but no abnormal enhancement and no mass or retrobulbar inflammation (Figure 2).

Lumbar puncture for CSF analysis revealed a normal opening pressure (15 cm H<sub>2</sub>O) and elevated concentrations of glucose (103 mg/dL) and protein (58 mg/dL). White blood cell count was within normal limits and differential analysis revealed 25% monocytes and 47% blasts. Gram stain, culture, fungal studies, and viral studies were negative. Flow cytometry revealed 41% myeloid blasts, consistent with relapse of AML. The following day, bone marrow biopsy was performed, revealing no bone marrow involvement.

## Treatment

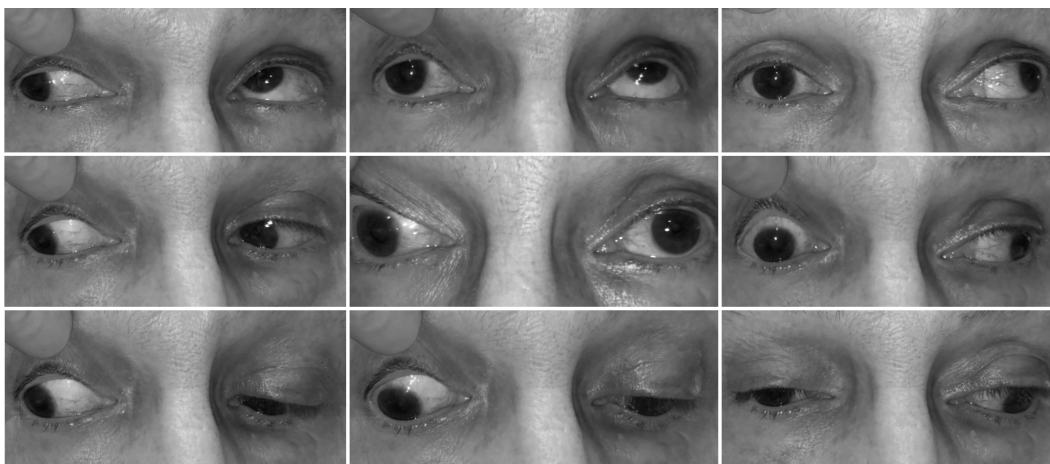Intrathecal chemotherapy was started on day 3, and the patient was discharged 4 days later with plans for weekly intrathecal chemotherapy (Figure 3). The

Published August 18, 2019.

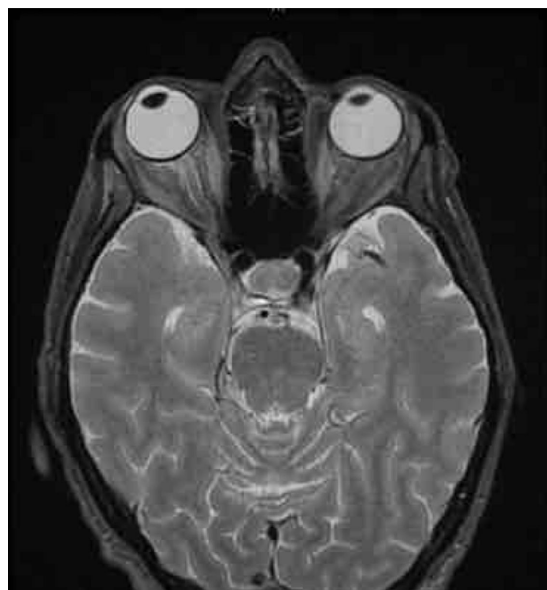Copyright ©2019. All rights reserved. Reproduction in whole or in part in any form or medium without expressed written permission of the Digital Journal of Ophthalmology is prohibited.

doi:10.5693/djo.03.2019.07.001

Correspondence: Anjolie K. Quick, MD, Assistant Professor of Ophthalmology, Comprehensive Ophthalmology, University of Kansas School of Medicine, 7400 State Line Road, Prairie Village, KS 66208 (email: aquick2@kumc.edu).



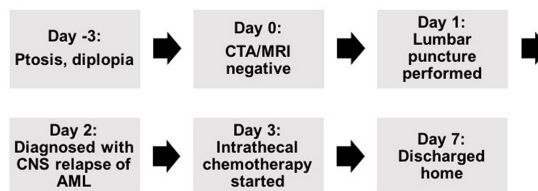
**Figure 1.** Ocular motility testing demonstrating impaired adduction, supraduction, and infraduction of the right eye. Left eye motility was full.



**Figure 2.** T2-weighted magnetic resonance imaging demonstrating mild right-sided proptosis and slightly increased cerebrospinal fluid signal surrounding the right optic nerve but no abnormal enhancement and no mass or retrobulbar inflammation.

patient's ophthalmic signs and symptoms, including diplopia, ptosis, and misalignment resolved 1 month after initiation of intrathecal chemotherapy. This coincided with the dissipation of myeloid blasts from the CSF. She has experienced no ophthalmic symptoms in the ensuing 8 months.

There was a brief reappearance of CSF myeloid blasts about 5 months after initiation of intrathecal chemother-



**Figure 3.** Timeline and hospital course. Imaging was obtained emergently to rule out aneurysm, followed by definitive diagnosis with lumbar puncture and treatment. *AML*, acute myeloid leukemia; *CTA*, computed tomography angiogram; *MRA*, magnetic resonance angiogram; *MRI*, magnetic resonance imaging.

apy that again resolved within 1 month. At 9 months, the patient's bone marrow biopsy and CSF analysis revealed no phenotypic evidence of AML, and the patient was deemed in complete remission.

## Differential Diagnosis

Isolated, pupil-sparing oculomotor nerve palsy is most often due to a microvascular cause, whereas isolated pupil-involving oculomotor nerve palsy is most commonly due to compression from an aneurysm or tumor.<sup>1</sup> Because of the potential for imminent subarachnoid hemorrhage caused by an intracerebral aneurysm, emergent imaging (magnetic resonance angiogram or CTA) is warranted in cases of oculomotor nerve palsy with partial or complete pupil involvement. While our patient's pupil was dilated, the pupillary light reflex was diminished but not absent. CTA was performed emergently to rule out intracranial aneurysm, followed by MRI, with and without contrast. In a study of 24 patients manifest-

ing similar presentations of *relative* pupil-sparing oculomotor nerve palsy,<sup>2</sup> Jacobson reported that 10 (42%) had microvascular involvement, 10 (42%) had mass lesions (aneurysm or tumor) compressing the nerve, and 1 (4%) had carcinomatous infiltration (from primary breast cancer). These findings illustrate the importance of the provider's certainty in non-pupil involvement when deciding to forego imaging studies, a course of action that should only be considered in patients over 50 years of age with atherosclerotic risk factors that increase the probability of microvascular involvement.<sup>3</sup>

When aneurysm was ruled out via imaging in this patient with a history of malignancy and immunosuppression, the differential diagnosis was narrowed to metastatic or infectious processes. As illustrated in our case, these etiologies can be differentiated by lumbar puncture and CSF analysis.

## Diagnosis

Central nervous system (CNS) involvement in AML is rare; therefore, AML patients without signs of CNS involvement do not routinely undergo diagnostic evaluation or prophylactic treatment for CNS involvement. The prevalence of CNS involvement in AML, however, is significantly higher at relapse (2.9%) than at initial presentation (0.6%).<sup>4</sup> CNS involvement is also more common in patients with myelomonocytic or monocytic leukemia.<sup>5</sup> The process by which leukemia spreads to the CNS may involve hematogenous spread or direct extension from cranial bone marrow to the dura and/or leptomeninges, termed *leptomeningeal lymphomatosis*.<sup>6</sup> Tumor cells that reach the CNS before treatment may be protected from stem cell therapy and chemotherapy by the blood-brain-barrier.<sup>7</sup> CNS recurrence is known to occur in hematologic malignancies after successful chemotherapy because of the presence of the blood-brain barrier, which may protect leukemic cells from the cytotoxic effects of treatment.<sup>8</sup>

Involvement of the bone marrow is usually seen in cases of AML CNS relapse, which occurs more often in those who have not undergone allogeneic hematopoietic stem cell transplantation.<sup>9</sup> However, even in cases without bone marrow involvement and with prior stem cell transplantation, suspicion for leptomeningeal metastasis must be high in patients with focal neurologic deficits and a history of leukemia or lymphoma. MR imaging should be obtained but may be normal in 29%–88% of patients with leptomeningeal metastasis.<sup>10–12</sup> Thus, CSF sampling should be performed, because it is more sensitive, with a false negative rate as low as 11% (and lower with repeat sampling).<sup>10,13</sup> Current guidelines recom-

mend CSF studies in conjunction with MRI in the initial workup of a patient with suspected leptomeningeal metastasis.<sup>14–16</sup> Once diagnosed, treatment consists of intrathecal chemotherapy with repeat clinical and CSF evaluation after induction therapy.<sup>15</sup>

To our knowledge, this is the first case of AML presenting as an isolated pupil-involving oculomotor nerve palsy due to leptomeningeal metastasis. Similar cases have been reported, but in those cases either the pupil was spared or other cranial nerves were involved in addition to the oculomotor nerve.<sup>17–20</sup> Furthermore, this is the only oculomotor nerve-involving case of AML relapse in which CNS involvement was not apparent on imaging. While similar manifestations of AML relapse have been described, all cases involving the oculomotor nerve presented with imaging findings correlating with clinically observed neurologic deficits.<sup>17–19</sup> Although our patient's MRI revealed mild proptosis, signs of oculomotor nerve dysfunction as evident on examination were absent on imaging.

A similar case of abducens nerve-involving AML relapse not apparent on imaging was recently described by Fozza et al.<sup>21</sup> That case parallels the present one insofar as it was in a patient in their first AML remission presenting with CNS relapse manifesting as a cranial nerve palsy in the absence of imaging findings that was ultimately diagnosed with CSF evaluation. Our patient had undergone hematopoietic stem cell transplantation, though, whereas the patient reported by Fozza et al had not, making our case somewhat more atypical, because CNS relapse is less common after stem cell transplantation.<sup>9</sup> Moreover, their patient presented with bilateral abducens nerve deficits and systemic symptoms characteristic of intracranial hypertension, including nausea, vomiting, and dizziness. The abducens nerve is particularly susceptible to elevated intracranial pressure, and as such it is possible that generalized intracranial hypertension was the cause of the patient's deficits rather than localized leptomeningeal invasion, as suspected in our patient, who only presented with an isolated, unilateral oculomotor nerve palsy and fatigue. Both patients illustrate the range of potential presentations and the importance of CSF evaluation in the assessment of a patient with suspected AML CNS relapse.

## Literature Search

PubMed was searched on December 9, 2019, without date or language restriction, using the following terms, singly and in combination: *acute myeloid leukemia* AND *leptomeningeal metastasis*, *oculomotor nerve*,

*oculomotor nerve palsy, relapse, or third nerve palsy; oculomotor nerve OR oculomotor nerve palsy AND cancer, etiology, leukemia, leptomeningeal metastasis, and leptomeningeal lymphomatosis.*

## References

- Fang C, Leavitt JA, Hodge DO, Holmes JM, Mohny BG, Chen JJ. Incidence and etiologies of acquired third nerve palsy using a population-based method. *JAMA Ophthalmol* 2017;135:23-8.
- Jacobson DM. Relative pupil-sparing third nerve palsy: etiology and clinical variables predictive of a mass. *Neurology* 2001;56:797-8.
- Sadagopan KA, Wasserman BN. Managing the patient with oculomotor nerve palsy. *Curr Opin Ophthalmol* 2013;24:438-47.
- Alakel N, Stölzel F, Mohr B, et al. Symptomatic central nervous system involvement in adult patients with acute myeloid leukemia. *Cancer Manag Res* 2017;9:97-102.
- Holmes R, Keating MJ, Cork A, et al. A unique pattern of central nervous system leukemia in acute myelomonocytic leukemia associated with inv(16)(p13q22). *Blood* 1985;65:1071-8.
- Azzarelli V, Roessmann U. Pathogenesis of central nervous system infiltration in acute leukemia. *Arch Pathol Lab Med* 1977;101:203-5.
- Cho WH, Choi YJ, Choi BK, Cha SH. Isolated recurrence of intracranial granulocytic sarcoma mimicking a falx meningioma in acute myeloblastic leukemia. *J Korean Neurosurg Soc* 2010;47:385-8.
- Krendel DA, Albright RE, Graham DG. Infiltrative polyneuropathy due to acute monoblastic leukemia in hematologic remission. *Neurology* 1987;37:474-7.
- Singhal S, Powles R, Treleaven J, et al. Central nervous system relapse after bone marrow transplantation for acute leukemia in first remission. *Bone Marrow Transplant* 1996;17:637-41.
- Clarke JL, Perez HR, Jacks LM, Panageas KS, Deangelis LM. Leptomeningeal metastases in the MRI era. *Neurology* 2010;74:1449-54.
- Singh SK, Leeds NE, Ginsberg LE. MR Imaging of leptomeningeal metastases: comparison of three sequences. *AJNR Am J Neuroradiol* 2002;23:817-21.
- Sze G, Soletsky S, Bronen R, Krol G. MR imaging of the cranial meninges with emphasis on contrast enhancement and meningeal carcinomatosis. *AJNR Am J Neuroradiol* 1989;10:965-75.
- Nayar G, Ejikeme T, Chongsathidkiet P, et al. Leptomeningeal disease: current diagnostic and therapeutic strategies. *Oncotarget* 2017;8:73312-28.
- Chamberlain M, Junck L, Brandsma D, et al. Leptomeningeal metastases: a RANO proposal for response criteria. *Neuro Oncol* 2017;19:484-92.
- Chowdhary S, Chamberlain M. Leptomeningeal metastases: current concepts and management guidelines. *J Natl Compr Canc Netw* 2005;3:693-703.
- Kesari S, Batchelor TT. Leptomeningeal metastases. *Neurol Clin* 2003;21:25-66.
- Tabata M, Yoshida M, Takahashi H, et al. Oculomotor nerve invasion of acute myelogenous leukemia demonstrated by magnetic resonance imaging. *Leuk Lymphoma* 1998;30:411-14.
- Haase R, Wiegand P, Hirsch W, et al. Unusual presentation of central nervous system relapse with oculomotor nerve palsy in a case of CD56-positive acute myeloid leukemia following allogeneic stem cell transplantation. *Pediatr Transplant* 2002;6:260-65.
- Al-Mujaini AS, Al-Dhuhli HH, Dennison DJ. Acute unilateral third nerve palsy as an early manifestation of central nervous system relapse in a patient with acute myeloid leukemia. *Saudi Med J* 2009;30:961-3.
- Saini JS, Mukherjee G, Mohan M. Acute myelomonocytic leukemia presenting as unilateral anterior cavernous sinus syndrome. *Indian J Ophthalmol* 1981;29:43-5.
- Fozza C, Dore F, Isoni MA, et al. Strabismus and diplopia in a patient with acute myeloid leukemia. *Am J Case Rep* 2014;15:288-90.