

Grand Rounds

A 71-year-old man with bilateral vision loss

Katy C. Liu, MD, PhD, Jullia A. Rosdahl, MD, PhD, and Mays A. El-Dairi, MD

Author affiliations: Department of Ophthalmology, Duke University, Durham, North Carolina

History

A 71-year-old white man presented to an outside hospital with acute bilateral vision loss of 1 week's duration. Five days prior to presentation he had been diagnosed with anterior uveitis by his primary ophthalmologist and was started on prednisolone acetate 1% and atropine eye drops. He reported a remote history of acute vision loss in the setting of a sinus infection with recovery of his vision following treatment of the infection.

The patient's symptoms did not improve, and he was transferred to a tertiary care facility for additional workup. On further questioning, the patient endorsed new-onset headache of 2–3 weeks' duration, severe pain with chewing, scalp pain, and weight loss. He denied recent eye or head trauma. He denied recent illness, fevers, chills, night sweats, cough, and shortness of breath. He denied recent alcohol or drug use, and he denied any history of sexually transmitted diseases.

Examination

Visual acuity in each eye was no light perception, without saccades to optokinetic drum. Pupils were fixed and dilated (on atropine). Intraocular pressure was 4 mm Hg in the right eye and 5 mmHg in the left eye. The external examination was notable for right upper eyelid ptosis. The slit-lamp examination of the right eye showed significant opacification and edema of the right cornea, no keratic precipitates, and a hazy view to the anterior chamber without frank hypopyon or posterior synechiae (Figure 1). Slit-lamp examination of the left eye showed trace corneal edema, no keratic precipitates, and no cell or flare in the anterior chamber.

Dilated fundus examination of the left eye was limited but showed 3+ optic nerve head edema. There was a cherry red spot. Arterioles were attenuated, and venules

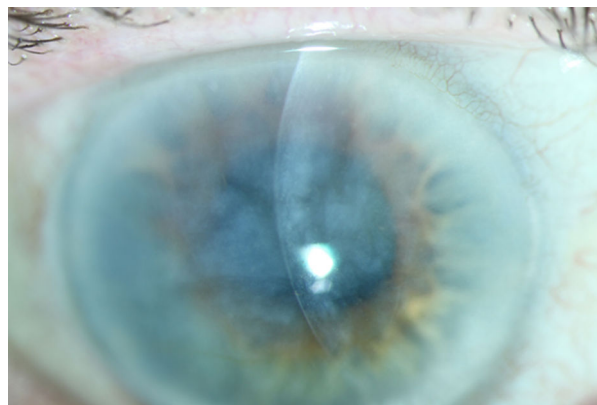


Figure 1. Anterior segment photograph of the right eye demonstrating an edematous and opacified cornea without keratic precipitates.

were dark and severely dilated (Figure 2). The peripheral retina was attached. There was no view posteriorly in the right eye.

Ancillary Testing

B-scan ultrasonography of the right eye showed no vitritis, posterior mass, or retinal detachment. In the left eye, optical coherence tomography (OCT) of the macula revealed diffuse macular thickening and enlarged venules (Figure 3). OCT of the retinal nerve fiber layer (RNFL) showed optic nerve head edema (Figure 4).

Complete blood count was within normal limits with the exception of an elevated platelet count ($484 \times 10^3/\text{mm}^3$). Basic metabolic panel was remarkable for low sodium (132 mEq/L), potassium (2.3 mEq/L), chloride (95 mEq/L), and brain natriuretic peptide (6 mg/dL). Inflammatory markers were elevated: erythrocyte sedimentation rate (ESR) was 59 mm/hr, and C-reactive pro-

Published September 3, 2017.

Copyright ©2017. All rights reserved. Reproduction in whole or in part in any form or medium without expressed written permission of the Digital Journal of Ophthalmology is prohibited.

doi:10.5693/djo.03.2017.03.002

Correspondence: Mays A. El-Dairi, MD, Duke University Eye Center, 2351 Erwin Road, DUMC 3802, Durham, NC 27710 (email: mays.el-dairi@duke.edu).

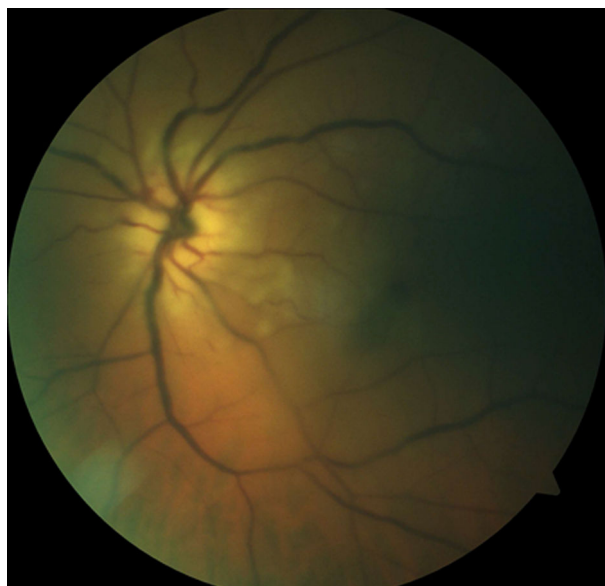

Figure 2. Fundus photograph of the left eye demonstrating a cherry-red spot, attenuated arterioles, and dark, dilated venules.

tein(CRP) was 7.53 mg/L (normal range, 0.02–0.7 mg/L). Additional testing that returned negative after diagnosis included purified protein derivative skin test, rapid plasma reagin, fluorescent treponemal antibody absorption test, anti-neutrophil cytoplasmic antibody (ANCA), and antinuclear antibody tests.

Maxillofacial computed tomography (CT) demonstrated no abnormalities. Magnetic resonance imaging (MRI) of the brain with and without contrast showed mild atrophy and chronic microvascular ischemic changes.

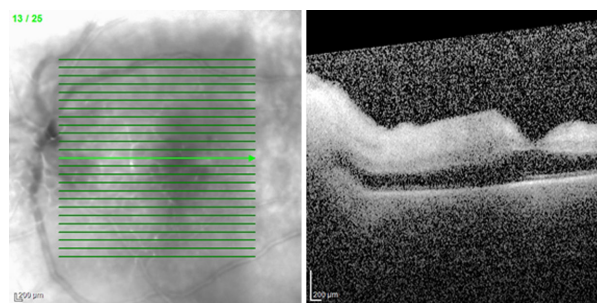


Figure 3. Optical coherence tomography (OCT) of the left eye revealed a diffusely thickened macula without fluid.

Treatment

Given the high clinical suspicion for giant cell arteritis (GCA), the patient was started on intravenous methylprednisone on admission and temporal artery biopsy was performed the following day. After 3 days of intravenous methylprednisone, the patient was transitioned to oral prednisone followed by a slow steroid taper as managed by rheumatology. The patient's inflammatory markers trended down with steroid treatment.

Differential Diagnosis

Although there was high clinical suspicion for GCA, the differential diagnosis included infectious and paraneoplastic etiologies such as syphilis and lymphoma. Syphilis can have a variety of ocular manifestations including keratitis, papilledema, vasculitis, and chorioretinitis. Primary intraocular lymphoma can present as nonspecific uveitis with vitritis, less often as retinal vasculitis or vas-

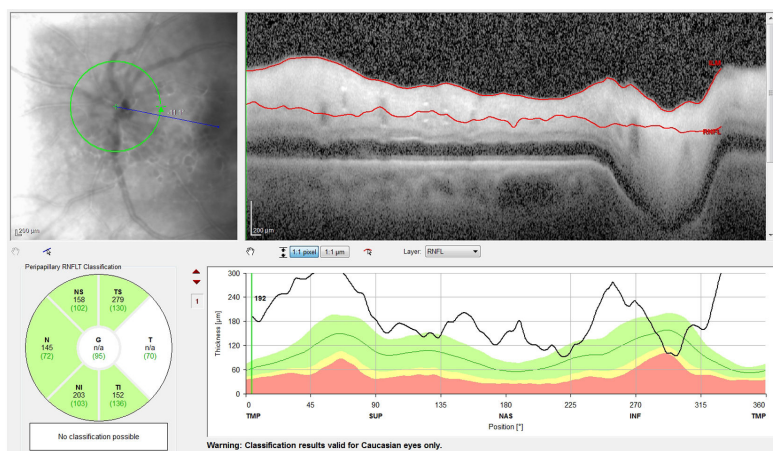


Figure 4. OCT retinal nerve fiber layer of the left eye showing thickening of the retinal nerve fiber layer around the disc suggesting optic nerve head edema.

cular occlusion. Although less likely, other vasculitic diseases were considered including lupus and ANCA-associated vasculitis.

Diagnosis and Discussion

Pathology of the temporal artery biopsy confirmed intense granulomatous arteritis (Figure 5). In this case, GCA presented as anterior segment ischemia that progressed to ophthalmic artery occlusion. In anterior segment ischemia, the anterior ciliary and long posterior ciliary arteries can be affected, leading to hypoxia, cell death, and inflammation.¹ Anterior chamber reaction can be the first sign of anterior segment ischemia, which likely led to the initial diagnosis of anterior uveitis in this case. Anterior segment ischemia can also manifest with hypotony and corneal edema due to ciliary body nonperfusion and corneal endothelial decompensation, respectively.

Although our patient was previously diagnosed with anterior uveitis, his clinical presentation, examination findings, and ancillary testing pointed to a vascular etiology of acute bilateral vision loss consistent with giant cell arteritis. In a patient >50 years of age, our history elicited several red flags, including severe new-onset headaches, jaw claudication, scalp tenderness, and recent unexplained weight loss.² In addition, his ESR and CRP were significantly elevated. Dilated examination of the left eye showed central retinal artery occlusion as well as involvement of posterior ciliary arteries with corneal opacification and hypotony due to anterior segment ischemia; together, the clinical picture favored occlusion of the ophthalmic artery.

It is important to consider the differential diagnosis for acute vision loss to no light perception, because there are few causes for such acute, profound vision loss. One must consider giant cell arteritis, other causes of ophthalmic artery occlusion, optic neuritis (neuromyelitis optica or multiple sclerosis), traumatic optic neuropathy, and nonorganic vision loss. In GCA, up to 21% of cases present with no light perception vision.³ Although GCA oftentimes presents with evidence of optic disc or retinal ischemia on clinical examination, GCA can less commonly present with anterior segment ischemia,⁴ posterior ischemic optic neuropathy, cranial nerve palsies, or Horner's syndrome.

The visual prognosis of this patient presenting with no light perception in both eyes is poor, and he was lost to follow-up after hospital discharge. In a patient with unilateral or less severe vision loss due to GCA, appropriate

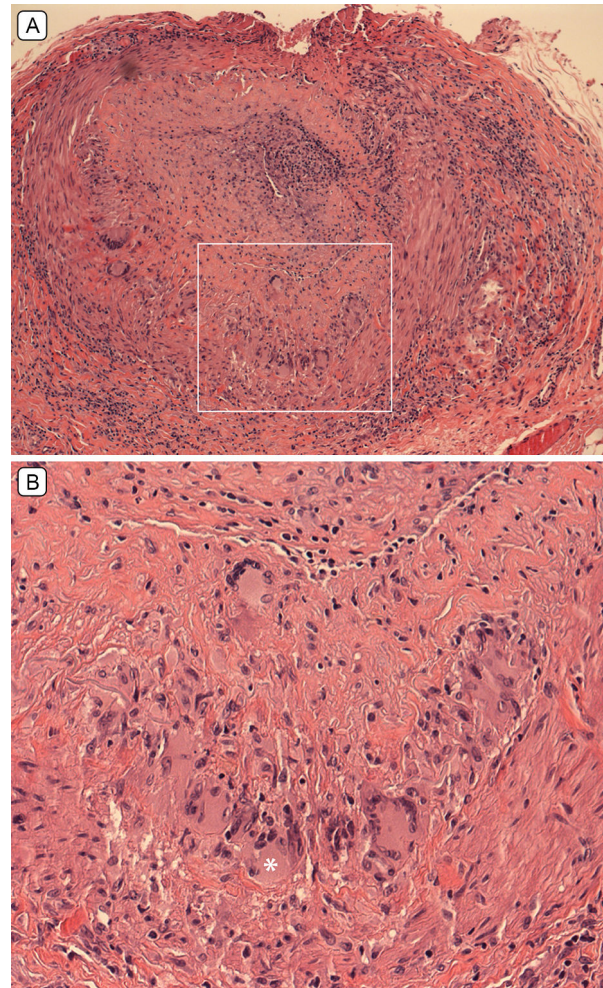


Figure 5. A, Histopathology (hematoxylin-eosin stain) of temporal artery biopsy showing “intense granulomatous arteritis,” with a nearly occluded artery lumen and inflammation in all vessel layers (original magnification $\times 10$). B, Higher magnification of the segment delineated by the whited box shows multinucleated cells, one of which is indicated by the asterisk (original magnification $\times 25$).

and timely treatment may prevent a devastating visual outcome.

References

1. Lee JP, Olver JM. Anterior segment ischemia. *Eye* 1990;4:1-6.
2. El-Dairi MA, Chang L, Proia AD, Cummings TJ, Stinnett SS, Bhatti MT. Diagnostic algorithm for patients with suspected giant cell arteritis. *J Neuroophthalmol* 2015;35:246-53.
3. Liu G, Glaser JS, Schatz NJ, Smith JL. Visual morbidity in giant cell arteritis: clinical characteristics and prognosis of vision. *Ophthalmology* 1994;101:1779-85.
4. McKillop E, Tejawani D, Weir C, Jay J. Anterior segment ischaemia with giant cell arteritis. *Can J Ophthalmol* 2006;41:201-3.