

## Grand Rounds

# A 35-year-old woman presenting with pain, reduced right-eye vision, and headache

Brinda P. Shah, MS, FRCOphth,<sup>a</sup> and Jonathan Clarke, MD, FRCOphth<sup>b</sup>

Author affiliations: <sup>a</sup>Moorfields Eye Hospital, London, United Kingdom;

<sup>b</sup>NIHR Biomedical Research Centre at Moorfields Eye Hospital NHS Foundation Trust and UCL Institute of Ophthalmology

## History

A 35-year-old woman presented to the emergency department of Moorfields Eye Hospital with a 10-day history of pain, reduced vision in her right eye, and headache. She described the visual disturbance as “sparkly lights.” She had undergone bilateral lensectomy at the age of 7 weeks for congenital cataract and was aphakic. Her corrected visual acuity was 6/36 in each eye with +19.0 D sphere correction.

For 2 years prior to this episode she complained of recurrent headaches every 2–4 months associated with similar visual aura. The headaches were not unilateral, and the visual symptoms were not limited to one side. She had been diagnosed with migraine in her teens; however, the headaches had now become more frequent, without change in nature. She described “flickering lights” that presented suddenly with reduced vision, “as if looking through a steamy window.” Each episode lasted 3–4 hours. She also noticed “rainbows” around bright lights, with “speckles, flashing lights, and blotches” in her vision. In the weeks before presentation, these attacks increased in frequency to almost daily, and sunlight was volunteered to be a trigger. There was no associated nausea, weakness, or other systemic symptoms. The ocular symptoms were now predominantly unilateral but similar to the symptoms that had been attributed to migraine in the past.

Previous assessments by ophthalmologists during the 2-year period prior to presentation found that her vision was stable, with deep anterior chambers. Vitreous was present up to the pupillary margin, but was not in the anterior chamber. The anterior hyaloid face was intact, intraocular pressures (IOPs) were normal, and the optic

discs were healthy. No focal defects were detected on visual field testing. On one previous visit, when her IOP in the right eye was found to be elevated, vitreous was noted in the anterior chamber, although there was no evidence of iris bombe. The angles were open on gonioscopy, with scattered peripheral anterior synechiae in 90°–180° in the right eye, whereas the left eye had open angles in all quadrants, with no synechiae. The past intraocular surgery was considered the likely etiology for the peripheral anterior synechiae. During this period, a neurologist confirmed that these episodes were representative of migraine.

## Examination

On presentation to the emergency department, her best-corrected Snellen visual acuity was 6/60 in the right eye and 6/36 in the left eye, with +19.0 D spherical correction in both eyes. On slit-lamp examination, the right eye had vitreous prolapsed into the anterior chamber, and gonioscopy revealed 360° of peripheral iridocorneal touch and closed angles. The IOP in the right eye was 62 mm Hg on Goldmann applanation tonometry. Fundus examination revealed healthy optic discs and retinae.

## Ancillary Testing

Anterior segment optical coherence topography was performed and demonstrated pupillary-block glaucoma, with anterior displacement of the iris and closure of the iridocorneal angles (Figure 1A).

## Treatment

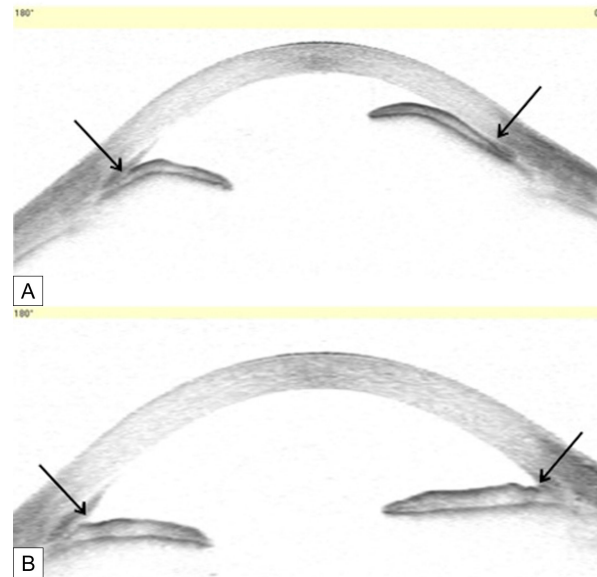
The acute pupillary block was managed with systemic and topical hypotensives (acetazolamide 250 mg and

Published May 13, 2015.

Copyright ©2015. All rights reserved. Reproduction in whole or in part in any form or medium without expressed written permission of the Digital Journal of Ophthalmology is prohibited.

doi:10.5693/djo.03.2015.03.002

Correspondence: Jonathan Clarke, Moorfields Eye Hospital, 162 City Road, London, EC1V 2PD United Kingdom (email: jonathan.clarke@moorfields.nhs.uk).



**Figure 1.** A, Anterior segment optical coherence tomography of patient with pupillary-block glaucoma with elevated intraocular pressure showing anterior bowing of the iris and closure of the iridocorneal angle (arrows). B, After treatment, the anterior chamber has deepened with open angles and a flat iris contour (arrows).

apraclonidine 0.5% eyedrops [apraclonidine was used because of its rapid onset of action]). Pupil dilation was achieved with atropine 1% eyedrops, thus relieving the pupil's compression of the vitreous at the pupil margin. The patient was laid supine to encourage backward displacement of the vitreous. Her IOP decreased to 40 mm Hg in an hour and to 9 mm Hg by the next morning. She then underwent an urgent surgical iridectomy and anterior vitrectomy. One week postoperatively, her visual acuity returned to the previous best-corrected Snellen visual acuity of 6/36, and the IOP was normal. The iris contour had become flat and the iridocorneal angles were open, as demonstrated by the anterior segment optical coherence tomography (Figure 1B). At final follow-up, 20 months after surgery, she has not suffered any further episodes of headaches or visual aura.

## Differential Diagnosis

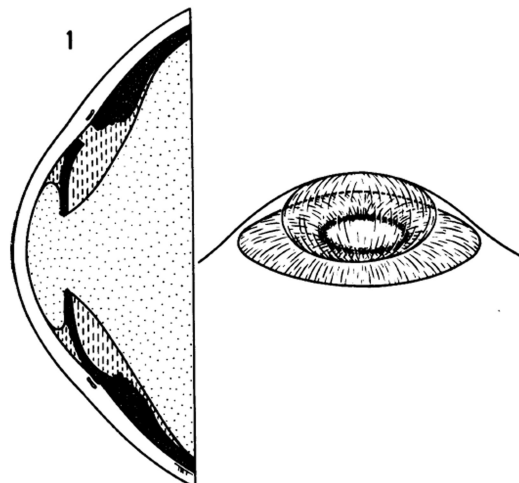
The recurrent, self-limiting and bilateral symptoms were suggestive of migraine. There was little to suggest recurrent episodes of elevated IOP, with the optic nerves being healthy. With the presentation of elevated IOP, however, acute episodes of elevated IOP were confirmed. The mechanism of this elevated IOP is discussed below. Malignant glaucoma (aqueous misdirection syndrome) would present with elevated IOP, but the short episodes would be unusual and the syndrome is very unusual in aphakic patients.

## Diagnosis and Discussion

Pediatric cataract surgery is still often performed without the insertion of an intraocular lens. Hitchings described acute, aphakic, pupillary-block glaucoma as “a relatively uncommon condition characterized by ocular hypertension, shallowing of the anterior chamber and marked convexity of the iris, together with angle closure.”<sup>1</sup> The pupil closes onto the vitreous, obstructing the route for aqueous to egress from the posterior chamber to the anterior chamber. Positive pressure in the posterior chamber in comparison to the anterior chamber forces vitreous anteriorly. The iris is also pushed anteriorly by the positive posterior chamber pressure. This explains the shallow anterior chamber and secondary closure of the iridocorneal angle. It can occur with an intact or broken anterior hyaloid face, but in both instances, vitreoendothelial contact is the rule.<sup>1</sup>

In this situation, Shaffer also describes the role of miotics in increasing the tension of the pupil causing a plugging effect on the vitreous thereby creating a resistance to aqueous outflow.<sup>2</sup> This may explain the reason for sunlight acting as a trigger for headaches in our patient, which were likely intermittent episodes of pupillary block.

An illustration from Hitching's 1979 paper is remarkably similar to the findings documented on the day of the acute episode (Figure 2).<sup>1</sup> There have been several



**Figure 2.** Cross-section and diagrammatic three-dimensional view indicating relationships between vitreous, aqueous and iris in aphakic pupil block.<sup>1</sup> (Reproduced with permission from Hitchings RA. Acute aphakic pupil block glaucoma: an alternative surgical approach. *Br J Ophthalmol* 1979;63:31–7.)

reports of intermittent-angle closure episodes (in phakic but not aphakic patients) misdiagnosed as migraine prior to arriving at the correct diagnosis. In these cases, there was an association with high hypermetropia or shallow anterior chambers, prompting ophthalmology referral. Assessment for angle width confirmed intermittent-angle closure.<sup>3–5</sup>

In aphakic pupillary block, the anterior chambers can be deep, except in an acute setting. Posner has described 3 stages of pupillary block by the vitreous, as follows: (1) an early stage, characterized by relative block due to decreased permeability of the hyaloid face; (2) a moderate stage, with adhesions between the vitreous and sphincter pupillae referred to as sphincteric pupillary block; and (3) the irido-hyaloidal stage, with extensive adhesions between the anterior hyaloid face and the entire posterior iris surface.<sup>6</sup>

The diagnosis requires careful history taking and identification of precipitating factors, such as those leading to pupil constriction. These factors include bright sunlight (as in the present case) or parasympathomimetics such as pilocarpine. The presence of vitreous at the pupil axis should raise concern about the possibility of future pupil block. Pupil block glaucoma is very unusual in the presence of a patent iridectomy.

The patient was managed with medical treatment, including topical atropine until the definitive surgical treatment. A laser iridotomy might also have broken the

pupil block, but the iris can be edematous with high IOP preventing a straightforward laser iridotomy.

A change in the nature of symptoms should alert the treating physician to look for pathology other than migraine to explain the nature of the symptoms.

### Acknowledgments

Supported by the National Institute for Health Research (NIHR) Biomedical Research Centre based at Moorfields Eye Hospital NHS Foundation Trust and UCL Institute of Ophthalmology. The views expressed are those of the authors and not necessarily those of the NHS, the NIHR or the Department of Health.

### References

1. Hitchings RA. Acute aphakic pupil block glaucoma: an alternative surgical approach. *Br J Ophthalmol* 1979;63:31–7.
2. Shaffer RN. The role of vitreous detachment in aphakic and malignant glaucoma. *Trans Am Acad Ophthalmol Otol* 1954;58:217.
3. Shindler KS, Sankar PS, Volpe NJ, Piltz-Seymour JR. Intermittent headaches as the presenting sign of subacute angle closure glaucoma. *Neurology* 2005;65:757–8.
4. Maggioni F, Dainese F, Mainardi F, Lisotto C, Zanchin G. Intermittent angle-closure glaucoma in the presence of a white eye, posing as retinal migraine. *Cephalgia* 2005;25:622–6.
5. Noshier R, Hering-Hanit R, Neshier G. Subacute glaucoma masquerading as migraine: how to avoid the pitfall and make the diagnosis. *Postgrad Med* 2006;119:70–3.
6. Posner A. Postcataract glaucoma associated with shallow anterior chamber. *Int Ophthalmol Clin* 1964;4:1029–43.