

Grand Rounds

A 71-year-old woman with decreased vision, nyctalopia, and peripheral vision loss

Ravi Parikh, MD, MPH,^a Miguel A. Materin, MD,^{a,b} Robert Lesser, MD,^c Joachim Baehring, MD, PhD,^{b,c} Mario Sznol, MD,^{b,e} and Jennifer A. Galvin, MD^a

Author affiliations: ^aDepartment of Ophthalmology and Visual Science, Yale University, New Haven, Connecticut;

^bSmilow Hospital at Yale New Haven Hospital;

^cEye Care Group, New Haven, Connecticut;

^dDepartment of Neurology, Yale University;

^eDepartment of Internal Medicine, Yale University

History

A 71-year-old woman was referred to the Department of Ophthalmology and Visual Science, Yale University, for an evaluation of decreased vision, worsening night vision, and peripheral vision loss in the left eye of 3 months' duration. She had a history of right ductal breast carcinoma in 1993 that was treated with a lumpectomy and radiation, with no known metastases. She also had a stage II-A melanoma of the left arm excised in 2011, gout, and hypertension. She denied flashes, floaters, or eye pain and had no history of eye surgery or eye trauma. Family history of eye disease was noncontributory.

Examination

On initial presentation, best-corrected visual acuity measured 20/20+ in each eye. Three months later, on presentation at Yale University, visual acuities were 20/25 +2 in the right eye and at 20/30 -1 in the left eye. Anterior segment examination in each eye was unremarkable except for 1+ nuclear sclerotic cataract in the right eye and trace cortical cataract in the left eye. Pupils were round and equally reactive, and there was no relative afferent pupillary defect. Ishihara plates were 14/14 in each eye. Ocular motility was full, and the patient was orthotropic.

Dilated fundus examination of the right eye showed no vitreous cells, a tilted, sharp, pink optic nerve, and a flat macula with a good foveal reflex. In the left eye, there were 2+ vitreous cells with a tilted optic nerve with tem-

poral pallor and a trace epiretinal membrane in the macula. Both optic nerves had a cup-to-disc ratio of 0.1. Retinal vasculature in both eyes showed mild arteriolar attenuation.

Goldmann visual field testing of the right eye showed I-4e reduced to 20° circumferentially and V-4e with mild reduction superiorly to 50° and mild reduction temporally to 70° (Figure 1A); in the left eye, I-3e reduced to 10° circumferentially and III-4e and V-4e moderately reduced to 35°–40° superiorly and reduced inferiorly to 55°–60° (Figure 1B).

Ancillary Testing

Magnetic resonance imaging of the brain with and without contrast was negative for metastatic disease. No further genetic tests for neoplasm were recommended by the oncology team.

Full-field electroretinogram (ff ERG) in each eye showed, in photopic (light adaptation) conditions, normal a-wave and decreased b-wave (Figure 2A). The a-wave was -40.13 μV in the right eye and -40.67 μV in the left eye as well as 14 ms and 17 ms, respectively (normal range, -31.17 ± 20.34 μV and 12.87 ± 2.05 ms). The b-wave was abnormal, at 66.4 μV in the right eye and 72.48 μV in the left eye and 38 ms (normal range, 117.1 ± 43.44 μV and 29.81 ± 3.88 ms). In single-flash scotopic (dark adaptation) conditions, there were broadened a-waves and decreased b-waves as well as a decreased b/a ratio. (Figure 2B). The a-wave is -213.6 μV in the right eye and -224 μV in the left eye as well

Published December 31, 2016.

Copyright ©2016. All rights reserved. Reproduction in whole or in part in any form or medium without expressed written permission of the Digital Journal of Ophthalmology is prohibited.

doi:10.5693/djo.02.2016.06.001

Correspondence: Ravi Parikh, MD, MPH, 40 Temple Street, 3rd floor, New Haven, CT 06510 (email: ravi.parikh@yale.edu).

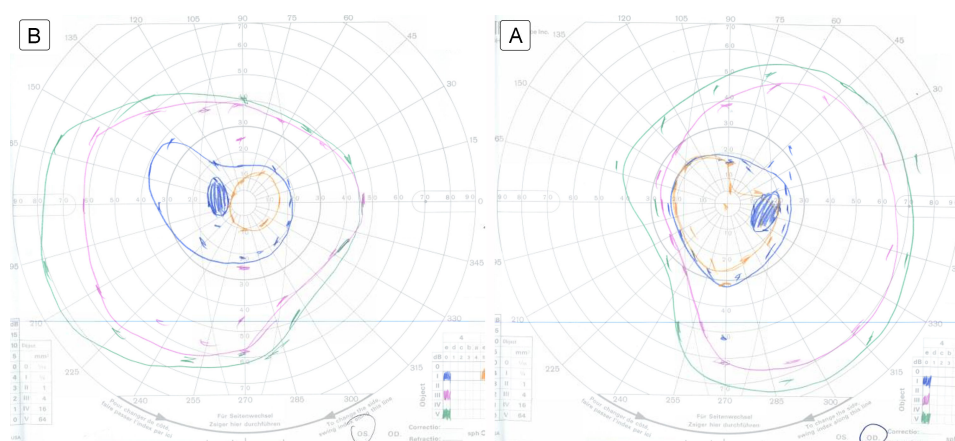


Figure 1. Goldmann visual field: left eye (A), right eye (B).

as 19 ms and 20 ms, respectively (normal range, $-154.3 \pm 73.08 \mu\text{V}$ and $15.5 \pm 6.13 \text{ ms}$). The b-wave in contrast was abnormal. The b-wave measured to $133.7 \mu\text{V}$ in the right eye and $117.6 \mu\text{V}$ in the left eye and 105 ms and 97 ms, respectively (normal range, $286.6 \pm 182.6 \mu\text{V}$ and $48.68 \pm 8.52 \text{ ms}$).

Laboratory work-up included an evaluation for paraneoplastic disease. Serum sent to Athena Diagnostics (Marlborough, MA) were negative for the antiretinal autoantibodies against the 23kDa cancer-associated retinopathy (CAR) recoverin protein; but serum sent to the Ocular Immunology Laboratory at Casey Eye Institute (Portland, Oregon) were positive for the antiretinal autoantibodies against the 46kDa enolase protein.

Vitreous biopsy of the left eye showed atypical lymphocytes, inconclusive for vitreous lymphoma. The flow cytometry result demonstrated a “paucicellular specimen with scattered atypical lymphocytes.”

Fluorescein angiogram showed no hallmark “leopard spot” changes at the level of the retinal pigment epithelium. Thus, the overall clinical picture was more suggestive of a smoldering low-grade vitritis rather than an ocular lymphoma.

Spectral domain optical coherence tomography (SD-OCT) of the maculae did not appear to show attenuation of the ellipsoid zone (Figure 3). Further fundus autofluorescence also did not show any ring maculopathy (Figure 4). Fundus photographs confirmed clinical examination findings, showing only a mild attenuation of the vessels with no apparent maculopathy in either eye (Figure 5).

A positron emission tomography computerized tomography (CT) scan showed hypermetabolic uptake in a 4.8 cm left axillary lymph node without any other pathologic uptake. A left axillary lymph node dissection revealed involvement of one lymph node for melanoma, whereas six additional lymph nodes were negative for metastatic disease.

Treatment

After the diagnosis of melanoma-associated retinopathy was made, our patient was treated with intravenous immunoglobulin (2 mg/kg) for 6 months, resulting in her having a stable visual acuity ($20/30 \pm 2$ in each eye). Of note, an improvement in her night vision was observed subjectively; however, repeat ffERG findings were unchanged.

Differential Diagnosis

Our differential diagnosis included intraocular lymphoma, melanoma-associated retinopathy (MAR), CAR, and metastatic disease.

Diagnosis and Discussion

CAR and MAR are both rare paraneoplastic syndromes that can be distinguished by clinical symptoms, fundus characteristics, and electrophysiology findings. Small-cell lung cancer has been most frequently reported as the primary cancer in CAR; breast and endometrial cancers have also been reported but less frequently.¹ CAR typically presents with loss of central vision, reduced color vision, a ring scotoma, photopsias, and decreased a-wave and b-wave on ffERG.² MAR typically presents with rapid onset of photopsias, scotomata, decreased

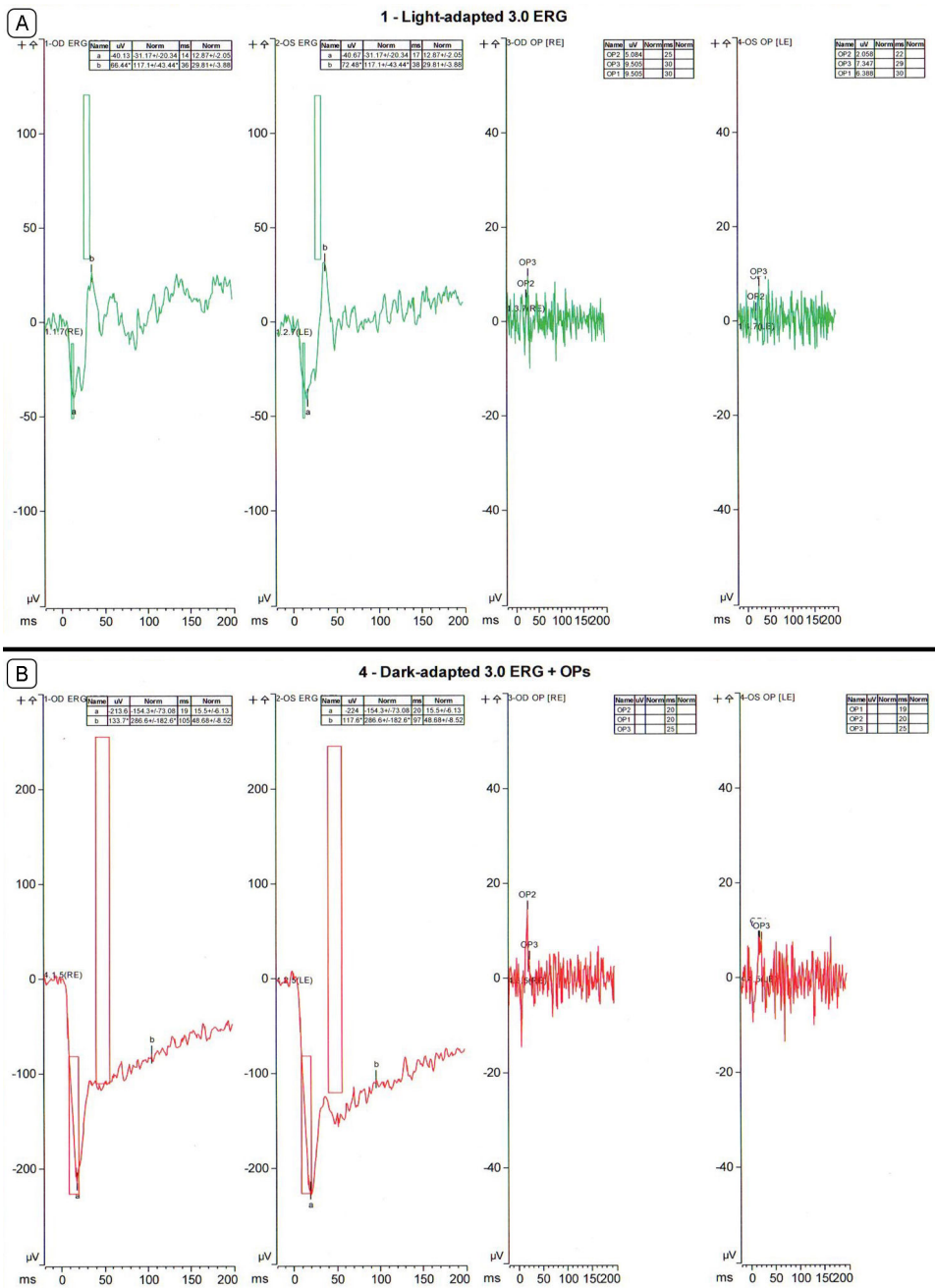


Figure 2. A, Photopic full-field electroretinogram (ffERG), right eye and left eye. B, Single-flash scotopic ffERG, right eye and left eye.

night vision, and variable loss of peripheral or paracentral vision.^{3,4}

Our patient had positive antiretinal autoantibodies against the 46-kDa enolase protein, which is also associated with CAR; but, positive antiretinal autoantibodies are also found in 10% of healthy patients and in various autoimmune diseases.⁵

Our patient did not have any other paraneoplastic or antiretinal autoantibodies. The ffERG finding helped confirm the diagnosis of MAR. The proposed pathophysiology of MAR is due to antibodies which target the depolarizing bipolar cells.⁶ In MAR, the photopic ffERG shows a decreased b-wave with a relatively normal a-wave, whereas the scotopic ffERG shows a markedly

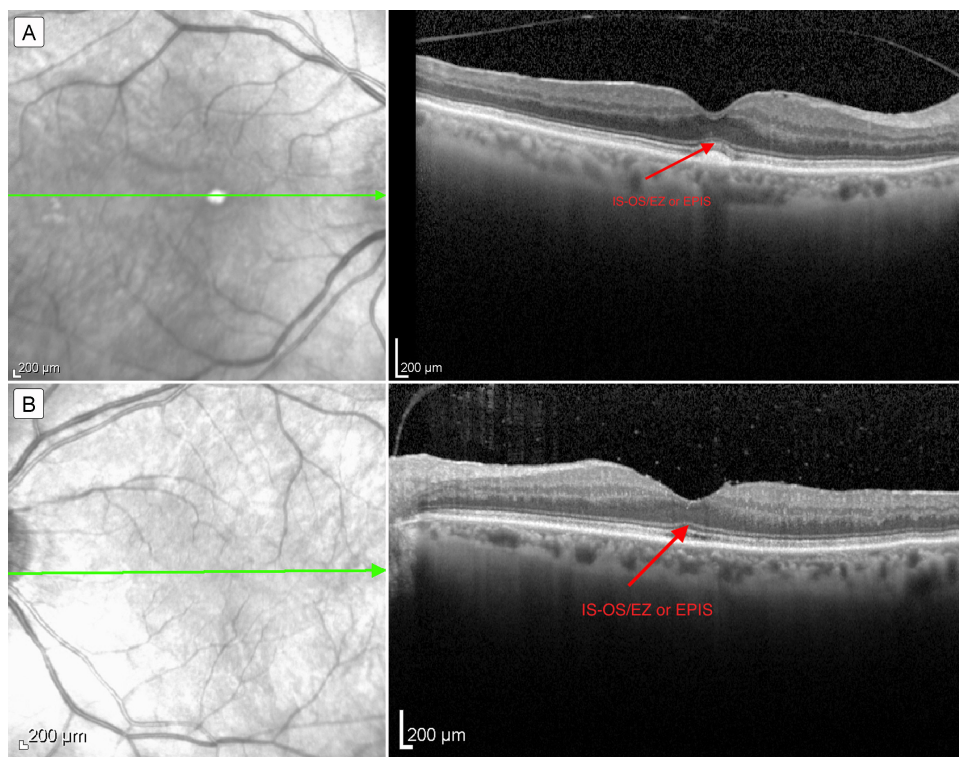


Figure 3. Optical coherence tomography of the macula: right eye (A) and left eye (B), with arrow indicating the inner segment–outer segment / ellipsoid zone or ellipsoid portion of inner segment (IS-OS/EZ or EPIS).

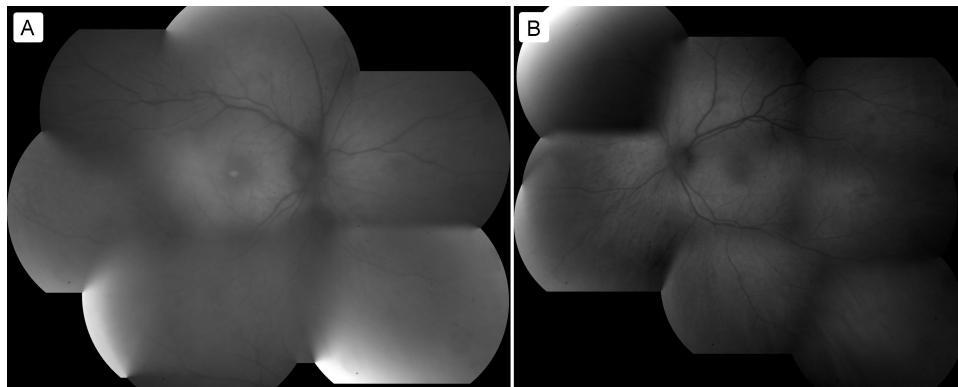


Figure 4. Fundus autofluorescence: right eye (A) and left eye (B).

decreased b wave with decreased b/a wave ratio. In CAR, on the other hand, the photopic and scotopic fERG shows a decreased a-wave and decreased b-wave.⁷

Both of these paraneoplastic syndromes can be treated with immunomodulation. Our patient was treated with intravenous immunoglobulin.⁸ Although no large randomized trials exist, visual improvement in CAR has

been reported in the majority of patients receiving corticosteroid treatment, although it has been noted that some patients with autoimmune retinopathies have improved with a combination of plasmapheresis and corticosteroid therapy.¹

Visual loss in patients with a cancer history may be due to paraneoplastic syndromes, treatment toxicity and ocular metastases. In addition to clinical evaluation, serologies

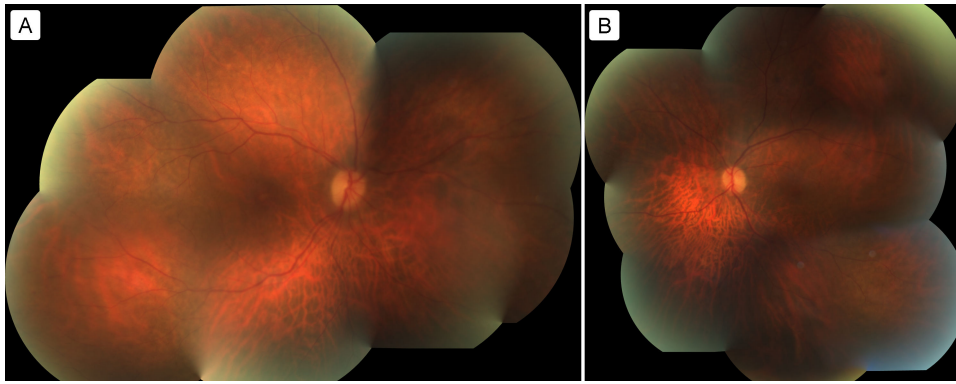


Figure 5. Fundus photographs of the right eye (A) and left eye (B).

and electrophysiology testing are important to establish a diagnosis. A diagnosis of a paraneoplastic disease should prompt evaluation of a patient for a primary cancer, metastatic disease, or progressing systemic cancer.

References

1. Hooks JJ, Tso MS, Detrick B. Retinopathies associated with antiretinal antibodies. *Clin Diagn Lab Immunol* 2001;8:853-8.
2. Goldstein SM, Syed NA, Milam AH, Maguire AM, Lawton TJ, Nichols CW. Cancer-associated retinopathy. *Arch Ophthalmology* 1999;117:1641-5.
3. Lu Y, Jia L, He S, et al. Melanoma-associated retinopathy: a paraneoplastic autoimmune complication. *Arch Ophthalmology* 2009;127:1572-80.
4. Myers DA, Bird BR, Ryan SM, et al. Unusual aspects of melanoma. Case 3. Melanoma-associated retinopathy presenting with night blindness. *J Clinical Oncology* 2004;22:746-8.
5. Grewal D, Fishman GA, Jampol LM. Autoimmune retinopathy and antiretinal antibodies: a review. *Retina* 2014;34:827-45.
6. Borkowski LM, Grover S, Fishman GA, Jampol LM. Retinal findings in melanoma-associated retinopathy. *Am J Ophthalmol* 2001;132:273-5.
7. Lei B, Bush RA, Milam AH, Sieving PA. Human Melanoma Associated Retinopathy (MAR) antibodies alter retinal-on response of the monkey ERG in vivo. *Invest Ophthalmol Vis Sci* 2000;41:262-6.
8. Guy J, Aptsiauri N. Treatment of paraneoplastic visual loss with intravenous immunoglobulin. *Arch Ophthalmol* 1999;127:612-4.