

Case Report

Spontaneous iris bleeding during cataract surgery in a patient with thrombocytopenia

Karen L. Christopher, MD, Ksenia Stafeeva, MD, and Michael S. Erlanger, MD

Author affiliations: Department of Ophthalmology, University of Colorado School of Medicine, Aurora, Colorado

Summary

A 91-year old man with a history of senile cataract and chronic lymphocytic leukemia (CLL), with a platelet count of 75,000/ μ L, presented for phacoemulsification and intraocular lens implantation in the left eye. A paracentesis made at the beginning of the procedure caused a small but not unusual amount of anterior chamber decompression. Spontaneous bleeding subsequently occurred from multiple sites on the iris surface. The bleeding was stopped by injecting hyaluronic acid into the anterior chamber to increase intraocular pressure. The remainder of the procedure was performed without complication, and resulting visual acuity improved from 20/70 preoperatively to 20/20⁻² with refraction 1 week postoperatively. In previously reported cases of intraocular bleeding during cataract surgery in thrombocytopenic patients, platelet counts were all \leq 55,000/ μ L.

Introduction

Bleeding complications occur during 0.2% of total cataract operations.¹ However, patients with thrombocytopenia are at a higher risk of intra- and postoperative spontaneous bleeding. One study found a 6% incidence of bleeding complication in thrombocytopenic patients (platelet count, $<$ 100,000/ μ L) in all ocular surgeries, all of which had platelets of \leq 55,000 cells/ μ L.² In another study, only 1 of 8 patients with thrombocytopenia (platelet count of $<$ 140,000/ μ L) developed bleeding complication during cataract surgery (platelet count, 36,000/ μ L).³ A study of 6 patients undergoing cataract surgery (platelet range, 33,000–98,000/ μ L) reported no bleeding complications.⁴

The 2003 British Committee for Standards in Haematology's guidelines for platelet transfusions recommends that the platelet count be raised to 100,000/ μ L prior to eye surgery.⁵ However, this guideline is based not on studies or case reports but only expert opinion (level 4) and applies to a broad range of ocular surgeries. No specific guidelines exist for relatively bloodless phacoemulsification procedures.

Case Report

A 91-year-old white man presented to the Denver VA Eye Clinic to be evaluated for cataract surgery. He complained of decreased vision, greater in the left eye than in the right eye, for the past several years; he was otherwise asymptomatic. On examination, best-corrected visual acuity was 20/50 in the right eye and 20/70 in the left eye. Slit-lamp examination was significant for 2+ nuclear sclerotic cataract in both eyes and 2+ posterior subcapsular cataract superiorly on the right and 3+ diffuse posterior subcapsular cataract on the left. The decision was made to perform phacoemulsification and intraocular lens implantation in the left eye.

The patient's past medical history was significant for chronic atrial fibrillation, for which he refused anticoagulation, and valvular heart disease. He was also recently diagnosed with chronic lymphocytic leukemia (CLL). His most recent blood count results were as follows: white blood cells, 17,800/ μ L; hemoglobin, 12.0 g/dL; hematocrit, 36.3%; and platelets, 107,000/ μ L. Considering the patient's age and the stability of his blood counts (Rai stage 1), the patient and his primary care physician had decided to monitor disease progression without treatment.

Published September 18, 2015.

Copyright ©2015. All rights reserved. Reproduction in whole or in part in any form or medium without expressed written permission of the Digital Journal of Ophthalmology is prohibited.

doi:10.5693/djo.02.2015.05.005

Correspondence: Karen L Christopher, MD, 1055 Clermont Street, Denver, Colorado 80220 (email: karen.christopher@ucdenver.edu).

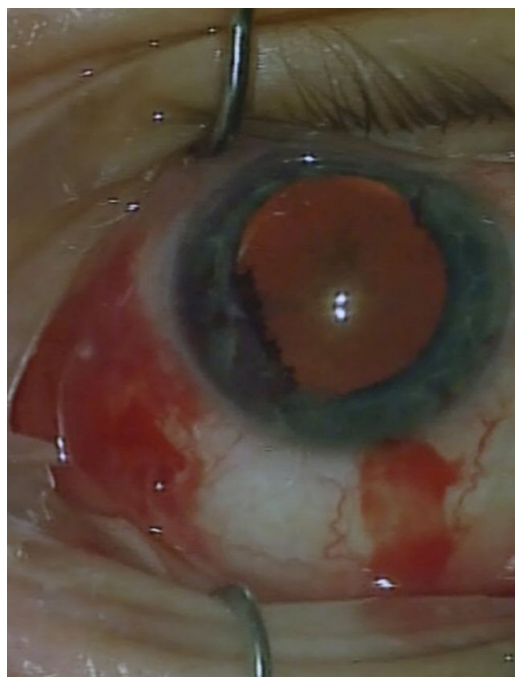
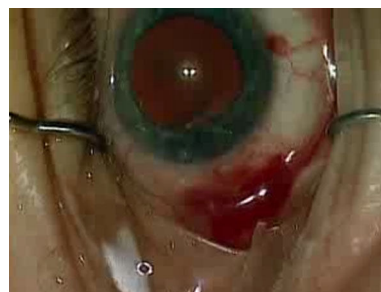

Figure 1. Image of the left eye during surgery showing spontaneous bleeding from multiple sites on the surface of the iris.

On the day of surgery, the patient's platelet count was 75,000/ μ L. The patient was placed under monitored anesthesia care as well as given proparacaine 0.5% topically and a sub-Tenon's anesthetic block of a 1:1 mixture of lidocaine 2% and bupivacaine 0.75%, without complication. Following a 1 mm paracentesis, there was a small amount of anterior chamber decompression, which was not concerning. Subsequently, however, multiple sites on the iris surface began to bleed spontaneously (Figure 1). There had been no trauma to the iris to set off this bleeding. Hyaluronic acid was injected into the anterior chamber to increase intraocular pressure and stop the bleeding. After several minutes of observation, there continued to be no bleeding. After a clear corneal wound was made and blood-tainted viscoelastic was removed, the anterior chamber was again filled with hyaluronic acid, and there was still no additional bleeding (Video 1). The remainder of the procedure proceeded without complication. During postoperative checks on day 1 and day 7, the patient did not have a hyphema or microhyphema. Best-corrected visual acuity had improved to 20/20⁻² on postoperative day 7.

Discussion

The low platelet count of 75,000/ μ L in our patient with CLL may have triggered spontaneous bleeding from



Video 1. Video showing the paracentesis followed by spontaneous iris bleeding, injection of hyaluronic acid, cessation of bleeding, clear corneal incision, removal of blood-tainted viscoelastic, and refilling of the chamber with hyaluronic acid without rebleed.

multiple sites of the iris during the normal decompression of the anterior chamber at the beginning of the case. Alternatively, this patient may have been affected by acquired von Willebrand syndrome (aVWS), an autoimmune phenomena known to be triggered by some cases of CLL.^{6,7} If so, the coagulation abnormality could have produced the spontaneous iris bleeding. Although a complication was avoided in this case, the circumstances could have easily threatened the desired outcome.

No guidelines exist for screening for aVWS in patients with CLL, and few studies have been published regarding cataract surgery in thrombocytopenic patients. Although Hay et al¹ and Jaffe et al² both published statistics on bleeding complications during cataract surgery based on retrospective reviews, their data was from a period when larger incisions were performed during cataract surgery; therefore, their data may not be fully applicable to complications related to modern surgical technique. In those studies, the highest platelet count in a thrombocytopenic patient with bleeding related to cataract surgery was 55,000/ μ L. More recent retrospective studies by Papatheakis et al³ and Kwong et al⁴ collectively noted only 1 case of bleeding related to cataract surgery, and this was in a patient with a platelet count of 36,000/ μ L.

The 2003 British Committee for Standards in Haematology, Blood Transfusion Task Force recommends transfusion to increase platelets to greater than 100,000/ μ L prior to eye surgery.⁵ However, as clear corneal phacoemulsification surgery is nearly bloodless, it seems likely that the optimal minimal platelet count required to perform this procedure safely is lower than that of many other ocular procedures. If the patient did indeed have aVWS, the 2007 guidelines from the US National Heart, Lung, and Blood Institute recommend that patients be considered for therapy with desmopressin and/or von

Willebrand factor concentrate prior to surgery.⁸ However, as the association between CLL and aVWS is not commonly encountered, screening for this potential complication was not performed.

To our knowledge, this represents the first reported case of intraocular bleeding related to cataract surgery in a patient with CLL and thrombocytopenia with platelet count of $>55,000/\mu\text{L}$. This case highlights the fact that patients with platelet counts as high as $75,000/\mu\text{L}$ should still be considered for platelet transfusion, and risk of acquired von Willebrand syndrome in patients with CLL should be considered prior to clear corneal phacoemulsification and IOL implantation to prevent intraocular bleeding.

Literature Search

PubMed was searched without language restriction in July 2012 using the the following terms and combinations of terms: *thrombocytopenia* AND *cataract*, *thrombocytopenia* AND *phacoemulsification*, *hyphema* AND *thrombocytopenia*, *iris* AND *bleed*.

References

1. Hay A, Olsen KR, Nicholson DH. Bleeding complications in thrombocytopenic patients undergoing ophthalmic surgery. *Am J Ophthalmol* 1990;109:482-3.
2. Jaffe, NS.; Jaffe, MS.; Jaffe, GF. *Cataract surgery and its complications*. 5th ed. ed. St Louis: C.V. Mosby Co; 1990. p. 498.
3. Papamatheakis DG, Demers P, Vachon A, Jaimes LB, Lapointe Y, Harasymowycz PJ. Thrombocytopenia and the risks of intraocular surgery. *Ophthalmic Surg Lasers Imaging* 2005;36:103-7.
4. Kwong YY, Lam RF, Yuen HK, Lam PT, Rao SK, Lam DS. Phacoemulsification in patients with thrombocytopenia. *J Cataract Refract Surg* 2005;31:1846-7.
5. British Committee for Standards in Haematology; Blood Transfusion Task Force. Guidelines for the use of platelet transfusions. *Br J Haematol* 2003;122:10-23.
6. Franchini M, Lippi G. Acquired von Willebrand syndrome: an update. *Am J Hematology* 2007;82:368-75.
7. Jung M, Rice L. Unusual autoimmune nonhematologic complications in chronic lymphocytic leukemia. *Clin Lymphoma Myeloma Leuk* 2011;11(Suppl 1):S10-3.
8. National Heart Lung, and Blood Institute. *The diagnosis, evaluation, and management of von Willebrand disease*. Bethesda, MD: National Institutes of Health; Dec. 2007 NIH publication no. 08-5832