

Case Report

Donor pericardium graft repair of traumatic globe rupture at previous trabeculectomy site

Brinda P. Shah, FRCOphth, and Jonathan Clarke, MD, FRCOphth

Author affiliations: Moorfields Eye Hospital, London, United Kingdom

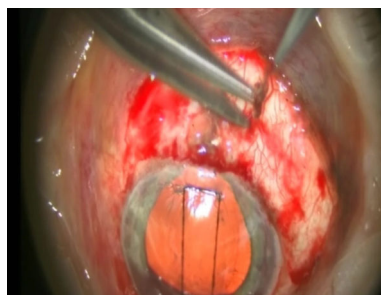
Summary

A 65-year-old man with a history of bilateral trabeculectomy augmented with mitomycin C underwent surgery for a scleral rupture following trauma. The site of the rupture was a posterior extension of the scleral flap. Attempted closure of a ragged scleral wound was not possible without excessive distortion and induced astigmatism. Persistent hypotony due to over drainage was treated by patching the site with a donor pericardium graft, secured with 10-0 nylon sutures. Although the trabeculectomy became nonfunctional and further glaucoma surgery was eventually required, a good visual outcome was achieved due to early repair following trauma.

Case Report

A 65-year-old man with bilateral augmented trabeculectomy presented at Moorfields Eye Hospital, London, with accidental trauma to the left eye by an opening car door. He complained of blurred vision and photophobia. His vision was 6/6 in his right eye and perception of light with full projection in his left eye. The intraocular pressures with Goldmann applanation tonometry were 7 mm Hg in the right eye and 0 mm Hg in the left eye. Examination of the affected eye revealed a hyphema covering half the anterior chamber; no obvious perforating injury was noted. Seidel's test was negative over the bleb area. He was phakic, and the lens capsule was intact, with no phacodonesis. The pupil was updrawn and gonioscopy confirmed iris entrapment in the sclerostomy. Subconjunctival hemorrhage was noted in the bleb area. B-scan ultrasound revealed no retinal detachment and no posterior segment rupture. He was started on topical and systemic antibiotics.

He was observed with bed rest for 48 hours, following which, on noting no improvement, a decision was made to examine the eye under anesthesia and repair a suspected rupture. The patient understood the risk of loss of glaucoma control.



Video 1. Surgical repair of traumatic globe rupture in the left eye of a 65-year-old man who had a previous trabeculectomy. The rupture was identified to be a posterior extension of the scleral flap. Attempted closure of a ragged scleral wound revealed persistent and excess aqueous drainage preoperatively. To overcome this, and to prevent future problems with hypotony, a pericardium graft was placed and sutured with 10-0 nylon sutures. Fluorescein was instilled to confirm there was no aqueous leak prior to conjunctival closure.

Surgical repair was carried out under general anesthesia on the third day after trauma (Video 1). The conjunctiva was dissected carefully away from the rupture site, and the limits of the rupture were identified. Care was taken not to compress the globe further and to ensure that all

Published August 31, 2014.

Copyright ©2014. All rights reserved. Reproduction in whole or in part in any form or medium without expressed written permission of the Digital Journal of Ophthalmology is prohibited.

doi:10.5693/djo.02.2013.09.003

Correspondence: Brinda Shah, Glaucoma Service, Moorfields Eye Hospital, 162 City Road, London EC1V 2PD, United Kingdom (email: drbrinda@hotmail.com).

Research was supported by the National Institute for Health Research (NIHR) Biomedical Research Centre based at Moorfields Eye Hospital NHS Foundation Trust and UCL Institute of Ophthalmology. The views expressed are those of the authors and not necessarily those of the NHS, the NIHR or the Department of Health.

adhesions between the conjunctiva and the prolapsed tissue were divided. The prolapsed iris was repositioned but remained close to the sclerostomy and was likely to occlude the sclerostomy. A broad iridectomy was then performed.

The sclerostomy was freed from uveal tissue by sweeping the wound with an iris reposer through the side port. The rupture was identified to be a posterior extension of the scleral flap. The rupture was closed with 10-0 nylon interrupted sutures. Importantly, the uveal tissue was not incarcerated into the wound. After attempted closure of a ragged scleral wound, persistent and excess aqueous drainage was observed (Video 1).

To prevent future hypotony, a pericardium graft (Tutoplast; IOP Ophthalmics, Costa Mesa, CA) was positioned and sutured with 10-0 nylon sutures placed as mattress sutures at the limbus and sides and interrupted sutures at the posterior edges. Fluorescein was instilled to confirm there was no aqueous leak. The conjunctiva was closed with 10-0 nylon interrupted sutures.

On the first day after surgery, the patient's vision improved to counting fingers in the presence of hyphema, but the intraocular pressure (IOP) was still low and warranted intracameral sodium hyaluronate injection, following which IOP increased to 5 mm Hg. Topical treatment included steroids, antibiotics, and atropine. Five days later the IOP was recorded as 12 mm Hg.

He was followed at a local eye department, where a spike in IOP was detected, for which he was started on two topical glaucoma medications and oral acetazolamide. The IOP was poorly controlled with medical treatment.

He subsequently underwent insertion of a glaucoma drainage device (Baerveldt 350 tube) 4 months after the rupture repair, achieving well-controlled IOP with the addition of a topical hypotensive. His visual acuity at last follow-up was 6/9 in the affected eye.

Discussion

It is recognized that incisional surgery, particularly on the cornea, is a risk factor for subsequent wound rupture.^{1,2} The wound healing response and the creation of scar tissue does not restore, and therefore have the same inherent strength as, the original collagen fibrils. This is particularly significant with trabeculectomy, where wound healing is suppressed by steroids and antimeta-

bollites, as minimal trauma has also been reported to lead to rupture after trabeculectomy.²

Tseng et al reported that rupture of the globe from trauma in patients who had undergone penetrating keratoplasty occurred in 2.5% of cases per year and only one-fifth preserved a clear graft after the trauma.³ The change in technique from extracapsular cataract surgery to phacoemulsification has reduced the risk of traumatic wound dehiscence from 0.4% in extracapsular surgery to 0.02% following phacoemulsification in a large retrospective review.⁴ Zeiter and Shin⁵ reported rupture following trauma after trabeculectomy in a series of 4 patients, of whom 3 had undergone previous combined cataract extraction with trabeculectomy and 1 had undergone trabeculectomy. Three of these patients developed scleral laceration extending posteriorly while one developed complete wound dehiscence of the scleral flap; all required surgical repair.

In contrast, Rubinstein and Salmon⁶ reported a patient with a history of multiple ocular surgeries, including trabeculectomy, who developed scleral flap dehiscence leading to hypotony and choroidal detachment, in the absence of prolapse of uveal tissue. This patient had a good visual outcome and the trabeculectomy remained functional on conservative management alone. Experimental work on the effect of trabeculectomy on ocular integrity to airbag trauma has been performed. Researchers identified that current airbag settings are capable of inducing globe rupture after a trabeculectomy.⁷ Scleral rupture extending from the scleral flap edge posteriorly was observed at impact velocities of over 30 m/sec, below the velocity of most standard airbags. This posterior extension of the scleral flap is a similar pattern of injury to that identified in this case. To date, there have been no reported cases of such incidents with airbags in the literature.

In our case, an extension of the sclerostomy site was identified during surgical repair after clearing the wound of prolapsed uveal tissue. This was the same as previously reported cases of trauma after trabeculectomy, where extension of the sclerostomy was noted.⁵⁻⁷ As this could not be completely closed with interrupted sutures, a patch graft was placed to help restore the integrity of the globe.

Donor patches (scleral, cornea, and pericardium) have been used to repair ruptures and perforations of the sclera and cornea but have not been previously reported in the context of ruptured trabeculectomy sites.^{8,9} Commonly, leaking blebs with melted sclera following antimetabolite use are patched. The technique we used in

the present case was not always possible in the past because scleral patches had to be ordered in advance, whereas the surgical decision is usually made intraoperatively when it becomes clearer that wound closure would be difficult if the trabeculectomy flap was friable. Now freeze-dried pericardium is readily available and can be stored at room temperatures for up to 5 years.

Wound closure without a patch graft would have led to significant induced astigmatism, whereas with our technique, the patient could eventually achieve an unaided visual acuity of 6/9 in the operated eye. This report highlights the importance of achieving early closure of the wound rather than aiming to maintain some trabeculectomy function after the rupture has occurred. The patient can also be appropriately warned about the need for future glaucoma surgery. Hence, there should be no hesitation in using a patch graft to achieve complete watertight closure at the time of primary closure.^{9,10}

References

1. Kloek CE, Andreoli MT, Andreoli CM. Characteristics of traumatic cataract wound dehiscence. *Am J Ophthalmol* 2011;152:229-33.
2. Greenfield DS, Parrish RK 2nd. Bleb rupture following filtering surgery with mitomycin-C: clinicopathologic correlations. *Ophthalmic Surg Lasers* 1996;27:876-7.
3. Tseng SH, Lin SC, Chen FK. Traumatic wound dehiscence after penetrating keratoplasty: clinical features and outcome in 21 cases. *Cornea* 1999;18:553-8.
4. Ball JL, McLeod BK. Traumatic wound dehiscence following cataract surgery: a thing of the past? *Eye (Lond)* 2001;15(Pt 1):42-4.
5. Zeiter JH, Shin DH. Traumatic rupture of the globe after glaucoma surgery. *Am J Ophthalmol* 1990;109:732-3.15
6. Rubinstein A, Salmon JF. Late traumatic scleral flap dehiscence following trabeculectomy. *Eye (Lond)* 2007;21:145-6.
7. Azukisawa M, Sato T, Ito Y, Kamezawa H, Nomura E, Nishide T, et al. Simulation of airbag impact on eyes after trabeculectomy by finite element analysis method. *Nippon Ganka Gakkai Zasshi* 2005;109:406-16.
8. Bochmann F, Azuara-Blanco A. Interventions for late trabeculectomy bleb leak. *Cochrane Database Syst Rev* 2012 Sep 12;9:CD006769.10.1002/14651858.CD006769.pub2
9. Sangwan VS, Jain V, Gupta P. Structural and functional outcome of sclera patch graft. *Eye* 2007;21:930-5.
10. Halkiadakis I, Lim P, Moroi SE. Surgical results of bleb revision with sclera patch graft for late-onset bleb complications. *Ophthalmic Surg Lasers Imaging* 2005;36:14-23.