

## Case Report

# Combined phacoemulsification with ExPRESS shunt in angle closure glaucoma

Aparna Rao, MD, FRCS

Author affiliations: LV Prasad Eye Institute, Patia, Bhubaneswar, Odisha, India

## Summary

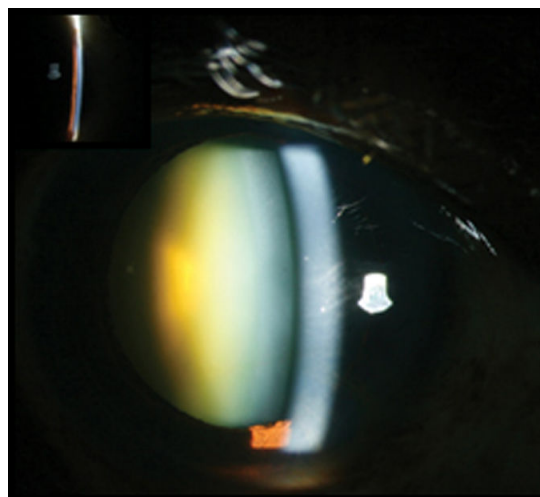
A 60-year-old woman diagnosed with primary angle closure glaucoma with extensive peripheral anterior synechiae (PAS) and advanced glaucomatous optic neuropathy unresponsive to maximal medical treatment, underwent clear corneal phacoemulsification and ExPRESS (Alcon Inc, Fort Worth, TX) shunt surgery in the right eye with intraoperative placement tailored to avoid areas of PAS. Postoperatively her visual acuity in the right eye was 20/20 and intraocular pressure was 13 mm Hg with the shunt in place and functioning bleb at final follow-up. The ExPRESS shunt can be used in angle closure eyes with good outcomes after proper placement of the shunt.

## Introduction

The ExPRESS shunt drainage device represents a recent innovation in glaucoma surgery.<sup>1-3</sup> It has gained popularity due to its relative ease of insertion, short learning curve for surgeons, and predictable results. Although the long-term results are not proven, angle closure is a contraindication for use of the ExPRESS shunt because of difficult placement patients with peripheral anterior synechiae (PAS), possible lumen blockage by the iris and inadequate space in shallow anterior chamber in eyes with angle closure glaucoma. We report use of the ExPRESS shunt in a patient with advanced primary angle closure glaucoma (PACG) and cataract.

## Case Report

A 60-year-old woman presented to the LV Prasad Eye Institute, Patia, Bhubaneswar, with gradual, painless decreased vision of 2 years' duration. The vision loss started in the right eye and then occurred in the left eye. On examination, her best-corrected visual acuity was counting fingers at 1 meter in the right eye and 20/200 in the left eye. Untreated intraocular pressure (IOP) by Goldmann applanation tonometry was 28 mm Hg in the right eye and 22 mm Hg in the left eye. Gonioscopy showed closed angles in both eyes with >180° PAS involving the temporal and superior quadrants but spar-



**Figure 1.** Preoperative slit-lamp photograph of the right eye of the patient showing shallow angle (inset) and a brunescens cataract.

ing the superonasal quadrant). Slit-lamp evaluation showed 3+ nuclear sclerosis in both eyes that precluded a clear view to the fundus (Figure 1). She underwent Nd:YAG laser peripheral iridotomy in each eye followed by fundus evaluation and visual field examination,

Published March 21, 2015.

Copyright ©2015. All rights reserved. Reproduction in whole or in part in any form or medium without expressed written permission of the Digital Journal of Ophthalmology is prohibited.

doi:10.5693/djo.02.2013.09.005

Correspondence: Aparna Rao, MD, FRCS, Head Glaucoma Services, LV Prasad Eye Institute, Patia, Bhubaneswar, Odisha-750124, India (email: aparna@lvpei.org).

which showed advanced glaucomatous cupping and a central island in each eye. Her IOP 1 week later was 26 mm Hg in the right eye and 16 mm Hg in the left eye on a fixed combination of brimonidine and timolol maleate. In view of significant cataract, advanced optic nerve damage, and uncontrolled IOP, we advised combined cataract extraction with intraocular lens implantation (IOL) implantation and glaucoma surgery.

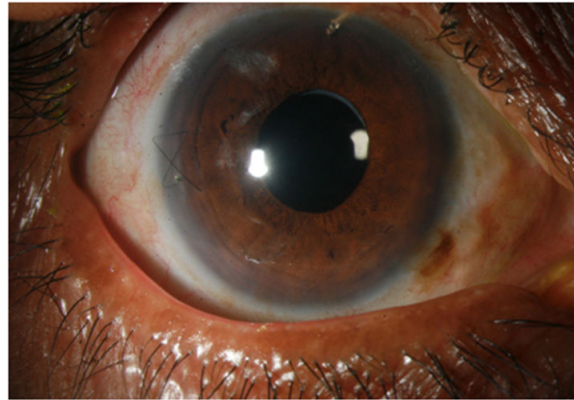
She underwent temporal clear corneal phacoemulsification surgery, IOL implantation, and ExPRESS minishunt (P50 version, Alcon Inc, Fort Worth, TX) implantation in the superonasal quadrant with a limbus-based conjunctival flap. Intraoperatively, the ExPRESS shunt was placed under a superficial scleral flap without complications. The sclera was closed using 10-0 nylon, and continuous 8-0 polyglactin 910 mattress sutures were used for conjunctival suturing. Postoperatively, her visual acuity in the right eye was 20/40; IOP was 13 mm Hg with the shunt in place and a functioning bleb. She was reexamined at 1 week, 1 month, and 3 months after surgery, with a final IOP of 13 mm Hg and a visual acuity of 20/20 in the right eye (Figure 2).

## Discussion

Trabeculectomy is currently the most widely practiced glaucoma filtration procedure.<sup>1</sup> We chose ExPRESS shunt surgery for this patient because it offered a standardized lumen, which safeguards against postoperative hypotony, and relative ease of insertion. Additionally, ExPRESS shunt surgery entails less tissue manipulation than trabeculectomy and has been shown to offer more consistent results and fewer complications, even for trainees.<sup>2,3</sup> Alternatives to this procedure could have included endoscopic cyclophotocoagulation, which was not available to us, and use of another valved shunt device, including the Ahmed glaucoma valve, which requires extensive conjunctival manipulation.

The ExPRESS device requires an open angle, and angle closure is currently contraindicated. Nevertheless our case responded well over a short follow-up of 3 months after placement of the shunt in the area free of PAS. To the best of our knowledge, there are no reported studies on the use of the ExPRESS shunt in angle closure glaucoma.

The low rate of complications may be attributable to the standard internal lumen.<sup>4-6</sup> This is of prime importance in angle closure glaucoma, where postoperative shallowing may be troublesome in an already narrow angle. Postoperative hypotony, in our case, could have also



**Figure 2.** Postoperative slit-lamp photograph showing intraocular lens and shunt in situ in the superonasal quadrant.

caused complete loss of optic nerve function, prompting our choice of ExPRESS shunt surgery. We also chose a two-site combined procedure for better functional outcome; a one-site procedure would probably have been difficult with the ExPRESS device because the entry wound created for an ostium would be large compared to that required for adequate placement of the device, leading to possible intraocular dislocation of the device.

With a relatively high proportion of primary angle closure glaucoma in Asia, ExPRESS shunt surgery seems to be a viable treatment option in advanced angle closure disease, with proper placement to avoid areas of PAS. Further studies are warranted to evaluate the efficacy of ExPRESS shunt surgery in the treatment of angle closure disease.

## Literature Search

The authors searched MEDLINE and PUBMED using the following terms: *ExPRESS*, *glaucoma*, *shunt procedures*, and *drainage devices*.

## References

1. Sugar HS. Some recent advances in the surgery of glaucoma. *Am J Ophthalmol* 1962;54:917-29.
2. de Jong LA. The ExPRESS glaucoma shunt versus trabeculectomy in open-angle glaucoma: a prospective randomized study. *Adv Ther* 2009;26:336-45.
3. Connor MA, Knape RM, Oltmanns MH, Smith MF. Trainee glaucoma surgery: experience with trabeculectomy and glaucoma drainage devices. *Ophthalmic Surg Lasers Imaging* 2010;41:523-31.
4. Sugiyama T, Shibata M, Kojima S, Ueki M, Ikeda T. The first report on intermediate-term outcome of ExPRESS glaucoma filtration device implanted under sclera flap in Japanese patients. *Clin Ophthalmol* 2011;5:1063-6.
5. Maris PJG, Ishida K, Netland PA. Comparison of trabeculectomy

with Ex-PRESS miniature glaucoma device implanted under scleral flap. *J Glaucoma* 2007;16:9-14.

6. Marzette L, Herndon L. A comparison of the ExPRESS mini glau-

coma shunt with standard trabeculectomy in the surgical treatment of glaucoma. *Ophthal Surg Lasers* 2011;42:453-9.