

## Grand Rounds

### A 26-year-old man with a blind spot in his left eye

Alfred White Jr, MD, Timothy Saunders, MD, and Peter Pavan, MD

Author affiliations: USF Eye Institute, University of South Florida

## History

A 26-year-old white man presented with a 4-day history of a scotoma in the left eye only. He characterized the visual field defect as greenish and fixed in a superotemporal, paracentral location. The visual change was sudden in onset and was not associated with other ocular complaints or headache. Past ocular history was remarkable only for a diagnosis of herpes simplex keratitis in the involved eye. One episode had occurred 13 years before. It was treated with trifluridine and was not complicated by scarring or recurrence. Past medical history was unremarkable. Social history was negative for antecedent travel, illicit drugs, or trauma, but was positive for cat exposure. Review of systems was negative.

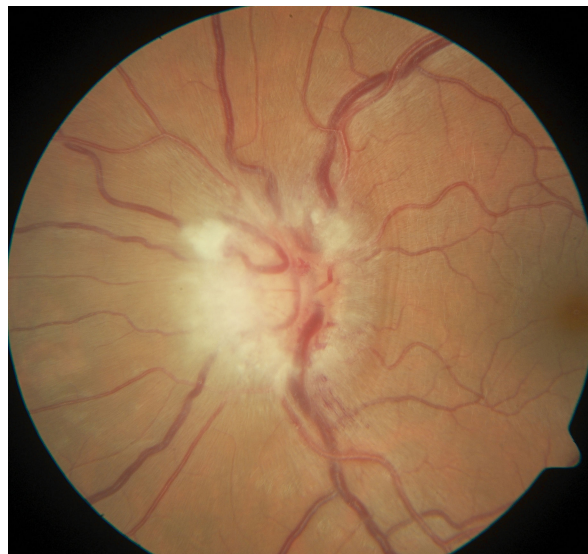## Examination

Visual acuity was 20/20 in each eye, with intraocular pressures of 15 mm Hg in the right eye and 16 mm Hg in the left eye. Pupils were regular, round, and reactive. A relative afferent pupillary defect was present in the left eye. Extraocular movements were full in both eyes. The patient endorsed temporal visual field loss in the left eye on confrontation. Slit-lamp examination of the anterior segment was unremarkable.

Dilated examination of the right eye was within normal limits. Examination of the left eye was pertinent for grade 1 vitreous haze (Figure 1) in the photographic scale described by Davis.<sup>1</sup> There was moderate optic nerve edema with adjacent flame hemorrhages (Figure 1). A small, 1/2 disc diameter area of nonspecific chorioretinal changes was noted in the inferotemporal mid-periphery without associated retinochoroiditis.

## Ancillary Testing

Optical coherence tomography (OCT) of the left eye showed peripapillary nerve fiber layer edema (Figure 2)



**Figure 1.** Color fundus photograph of the left eye. There is optic nerve edema and flame hemorrhage; vitreous haze, grade 1, was also appreciated.

and a small, shallow, serous retinal detachment nasal to the nerve (Figure 3). Late phase fluorescein angiography demonstrated staining of the left optic nerve (Figure 4). The macula displayed normal fluorescence.

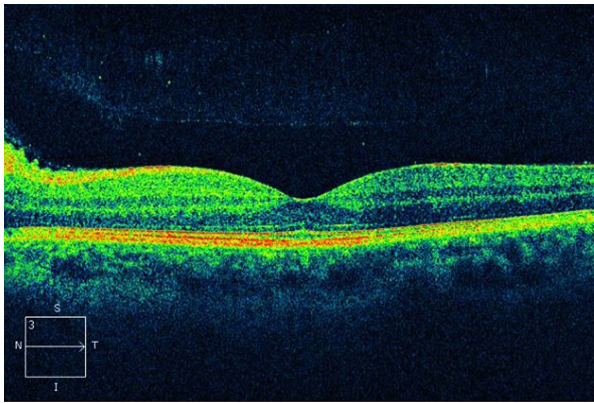
The workup of this patient included complete blood count, basic metabolic panel, B12, folate, angiotensin converting enzyme (ACE), antinuclear antibody (ANA), Bartonella and toxoplasma serologies, and fluorescent treponemal antibody (FTA-Abs). HIV testing was deferred. A lumbar puncture was performed, with an opening pressure of 20 cm H<sub>2</sub>O. Cerebrospinal fluid was analyzed for cryptococcal antigen, oligoclonal bands, Herpes simplex virus (HSV) 1 and 2 polymerase chain reaction (PCR), cytomegalovirus (CMV) PCR, and India ink.

Published September 25, 2013.

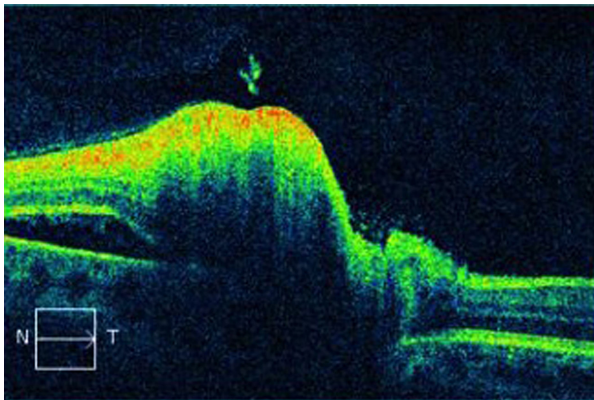
Copyright ©2013. All rights reserved. Reproduction in whole or in part in any form or medium without expressed written permission of the Digital Journal of Ophthalmology is prohibited.

doi:10.5693/djo.03.2013.07.001

Correspondence: Peter Reed Pavan, USF Eye Institute, 12901 Bruce B. Downs Blvd., MDC 21, Tampa, FL 33612 (email: p-pavan@health.usf.edu).



**Figure 2.** Macular optical coherence tomography (OCT) of the left eye showing peripapillary nerve fiber layer edema.



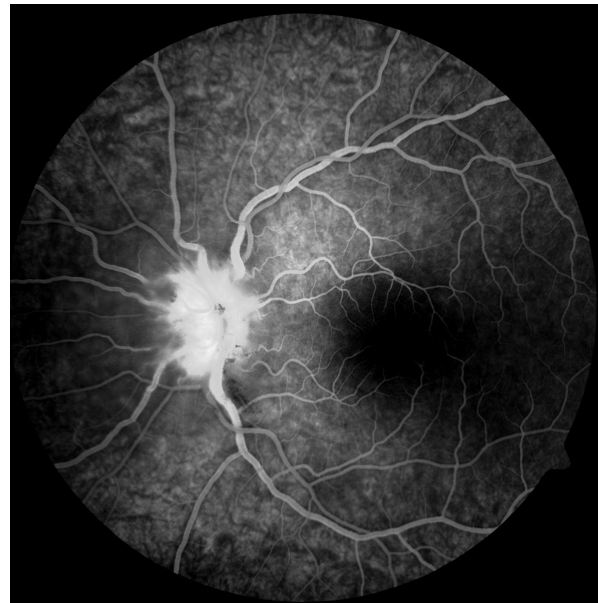
**Figure 3.** Peripapillary OCT of the left eye. Nerve fiber layer thickening and a neurosensory detachment nasal to the nerve are present.

Magnetic resonance imaging (MRI) and magnetic resonance angiography (MRA) of the brain and orbits was performed with and without contrast, demonstrating normal signal of the optic nerves.

All of the test results were negative, except for *Toxoplasma* serologies, which were equivocal for Immunoglobulin M (IgM). This prompted repeat testing, which was positive for both IgG and IgM.

## Treatment

Our patient was treated with a regimen of clindamycin 300 mg 4 times daily, trimethoprim/sulfamethoxazole double strength twice daily for 2 months, and concomitant prednisone 20 mg 4 times daily due to the severity of optic nerve involvement. Over the next 2 months, the prednisone was tapered to 5 mg daily. After 2 months of



**Figure 4.** Fluorescein angiography of the left eye at 1:05.7 demonstrating hyperfluorescence and staining of the optic nerve.

follow-up, he showed resolution of disc edema, macular edema, and extramacular serous retinal detachment but only mild improvement of the original scotoma. This response was consistent with the higher likelihood of permanent visual field changes in toxoplasmic neuroretinitis.<sup>2</sup> Ultimately, the patient was lost to follow-up, but when he was contacted 2 years after the initial episode, he reported no recurrence of symptoms.

## Differential Diagnosis

Neuroretinitis with vitreous cells has a diverse differential diagnosis. Infectious sources that can present similarly include syphilis, *Bartonella*, *Toxoplasma gondii*, *Toxocara*, HIV, HSV, CMV, tuberculosis, *Borreliaburgdorferi*, *Leptospira interrogans*, *Rickettsia typhi*, cysticercosis, and *Aspergillus*.<sup>3,4</sup> Inflammatory conditions such as multiple sclerosis, sarcoidosis, and systemic lupus erythematosus also have similar presentations. Neoplastic diseases such as meningioma, glioma, central nervous system lymphoma, and infiltrative metastatic disease with leptomeningeal involvement should also be included in the differential diagnosis. Conditions such as myelinated nerve fiber layer, and optic disc drusen can be mistaken for neuroretinitis. Vascular diseases, including non-arteritic and arteritic anterior ischemic optic neuropathy, diabetic retinopathy, radiation retinopathy, and central retinal vein occlusion, also bear a resemblance when papillitis is present. True papilledema due to increased intracranial pressure, through its vari-

ous mechanisms, should be included in the work-up.<sup>5</sup> Toxic causes such as methanol, ethylene glycol, and ethambutol are unlikely in the presence of vitreous cells.

## Diagnosis and Discussion

This clinical presentation is consistent with *Toxoplasma* neuroretinitis, which was confirmed by serology. Patients with neuroretinitis typically present with decreased visual acuity, from 20/50 to 20/200, and visual field defects usually in the ceocentral or central distribution. Stellate maculopathy and disc edema are the hallmark findings and may coincide with an adjacent serous retinal detachment.<sup>2</sup> Disc edema is often the initial sign followed by macular star formation approximately 1 week later with resolution of the peripapillary exudate. Vitreous cells usually are present without an anterior chamber response.<sup>6</sup> Recurrence, although rare, is most commonly associated with ocular toxoplasmosis.<sup>2</sup>

Fluorescein angiography findings typically include late phase disc staining. Capillaries supplying the optic nerve head demonstrate leakage that usually persists after resolution of the edema. Perifoveal capillary leakage is virtually nonexistent.<sup>6</sup>

Most cases of ocular toxoplasmosis are acquired instead of congenital.<sup>7</sup> The classic lesion in ocular toxoplasmosis is a focus of active retinochoroiditis adjacent to an old scar. The theory for the pathophysiology of this lesion is reactivation of *Toxoplasma* tissue cysts in the retina.<sup>8</sup>

Ultimately, our patient exhibited a toxoplasmic neuroretinitis, making this an atypical presentation of ocular toxoplasmosis. Other atypical forms include occlusive retinal vasculitis, retinal detachment, pigmentary retinopathies, panuveitis, optic neuropathy, and scleritis.<sup>9</sup> The presentations of toxoplasmosis are numerous and diverse.

*Toxoplasma* infection begins with ingestion of oocysts present in contaminated food and water sources.<sup>4</sup> While hematogenous spread is the most widely accepted route of infection, it has also been postulated that *Toxoplasma* can demonstrate a predominantly neuronal spread to the eye by way of the brain and optic nerve.<sup>8</sup> This is supported by the preponderance of juxtapapillary lesions seen in certain patient populations.<sup>8</sup> One retrospective study of 51 patients with active ocular toxoplasmosis with optic nerve involvement differentiated lesions into five categories<sup>10</sup>:

- Juxtapapillary retinochoroiditis—chorioretinal lesion contiguous with a swollen optic disc (33.3%)
- Pure papillitis—swollen optic disc, peripapillary vein sheathing plus a healed toxoplasmic scar (5.9%)
- Neuroretinitis—swollen disc, papillomacular or macular serous detachment, and hard exudates in the macula
- Distant lesion—swollen disc and a distant active lesion (43.1%)
- Mixed—any combination of the previous categories (15.7%)

The most serious potential complication of ocular toxoplasmosis is *Toxoplasma* encephalitis. This fatal complication is typically seen in immunocompromised hosts.<sup>11</sup> A PubMed search revealed only one reported case of ocular toxoplasmosis with encephalitis in an immunocompetent person.<sup>12</sup> The patient had *Toxoplasma* retinochoroiditis without neuroretinitis. Despite the absence of large studies on the incidence of encephalitis in patients with *Toxoplasma* neuroretinitis, likely due to its rarity, one should have a high index of suspicion and rule-out brain involvement in all patients with neurologic findings. In fact, it may be prudent to obtain baseline neuroimaging in all patients with suspected *Toxoplasma* neuroretinitis.

Ocular toxoplasmosis remains a clinical diagnosis, typified by a focus of retinochoroiditis with vitreous inflammation and an adjacent chorioretinal scar. Serology, while useful in identifying primary infection, is limited in differentiating between recurrent acquired and recurrent congenital infection. IgM confirms primary infection, and remains positive for approximately a year. In contrast, IgG is detectable for life, in both congenital and acquired infections.<sup>11</sup> One study detected measurable rises of IgG in patients with active recurrent disease (typical and atypical) compared to patients with latent disease or seropositive nonspecific uveitis.<sup>13</sup> When serologies are equivocal, PCR analysis of intraocular fluid for parasites provides more robust diagnostic data.<sup>14</sup> Our patient was both IgG and IgM positive, which suggests a recently acquired infection.

Triple therapy for ocular toxoplasmosis is classically a combination of pyrimethamine, sulfadiazine, and prednisone. Due to high rates of intolerance and serious adverse effects, alternative treatment, such as trimethoprim/sulfamethoxazole and clindamycin, may be

employed, and is supported by published trials yielding comparable results.<sup>6,15</sup>

Although toxoplasmosis rarely presents as neuroretinitis, the disease may have severe, even fatal, complications; thus it should be regularly considered as part of the differential diagnosis.

## References

1. Davis JL, Madow B, Cornett J, et al. Scale for photographic grading of vitreous haze in uveitis. *Am J Ophthalmol* 2010;150:637-41.e1.
2. Cunningham, ET, Jr. What diseases should I consider in a patient with neuroretinitis?. In: Foster, CS.; Hinkle, DM.; Opremcak, EM., editors. *Curbside Consultation in Uveitis*. Thorofare, NJ: Slack Book Incorporated; 2012. p. 103-6.
3. Folk JC, Lobes LA. Presumed toxoplasmic papillitis. *Ophthalmology* 1984;91:64-7.
4. Gess A, Wender J, Jumper JM, Cunningham ET Jr. The red eye from Rio. *EyeNet* May;2011 :1-2.
5. Purvin V, Sundaram S, Kawasaki A. Neuroretinitis: review of the literature and new observations. *J Neuroophthalmology* 2011;31:58-68.
6. Ray S, Gragoudas E. Neuroretinitis. *Int Ophthalmol Clin* 2001;41:83-102.
7. Holland GN. Reconsidering the pathogenesis of ocular toxoplasmosis. *Am J Ophthalmol* 1999;128:502-5.
8. Roberts F, McLeod R. Pathogenesis of toxoplasmic retinochoroiditis. *Parasitol Today* 1999;15:51-7.
9. Smith JR, Cunningham ET Jr. Atypical presentations of ocular toxoplasmosis. *Curr Opin Ophthalmol* 2002;13:387-92.
10. Eckert GU, Melamed J, Menegaz B. Optic nerve changes in ocular toxoplasmosis. *Eye* 2007;21:746-51.
11. Bonfioli AA, Orefice F. Toxoplasmosis. *Semin Ophthalmol* 2005;20:129-41.
12. Waragai M, Takaya Y, Hayashi M. [a case of toxoplasmic chorioretinitis and meningoencephalitis in an immunocompetent adult]. *Rinsho Shinkeigaku* 1995;35:559-62.
13. Papadia M, Aldigeri R, Herbot CP. The role of serology in active ocular toxoplasmosis. *International Ophthalmology* 2011;31:461-5.
14. Rothova A. Ocular manifestations of toxoplasmosis. *Curr Opin Ophthalmol* 2003;14:384-8.
15. Commodaro AG, Belfort RN, Rizzo LV, et al. Ocular toxoplasmosis—an update and review of the literature. *Oswaldo CruzMem Inst* 2009;104:345-50.