

Grand Rounds

A 54-year-old woman with bluish discoloration of her sclera

Isabella Phan, MD,^a Rachel Kaiser, MD, MPH,^b and Cynthia Chiu, MD^b

Author affiliations: ^aOregon Health and Science University;

^bUniversity of California, San Francisco

History

A 54-year-old, lightly pigmented woman of African, Indian, and Caucasian descent was noted to have a bluish discoloration of her sclera on routine examination by her optometrist. She was seen by a rheumatologist, who referred her to the ophthalmology service for evaluation of possible bilateral scleromalacia. At presentation, the patient noted an asymptomatic, nonprogressive, bluish discoloration of her sclerae for over 10 years. She had a history of osteoarthritis in her knees and wrists. Her current medications included a multivitamin, glucosamine, and a calcium supplement. She had a 10-year history of tetracycline use (over 1825 grams total) followed by an additional 20 years of minocycline use (1460 grams total) for acne. She had discontinued minocycline 2 years prior to presentation.

Examination

On examination, the patient's visual acuity was 20/25 bilaterally. Her pupillary examination, intraocular pressures, extraocular movements, and confrontational visual fields were all normal. She had dark-brown and blue discoloration of the sclera circumferentially approximately 4 mm posterior to the limbus bilaterally, most concentrated nasally and temporally (Figures 1 and 2). There was no scleral thinning or injection. Her corneas were clear with no keratic precipitates. The anterior chambers were quiet. Her lenses, vitreous, and retinae were unremarkable, with no evidence of vasculitis, uveal tumors, or intraocular inflammation. Closer inspection of the patient's face revealed bluish discoloration of the lateral canthi and lower eyelid skin bilaterally, the pinna of both ears, and her front teeth (Figures 3 and 4). Her

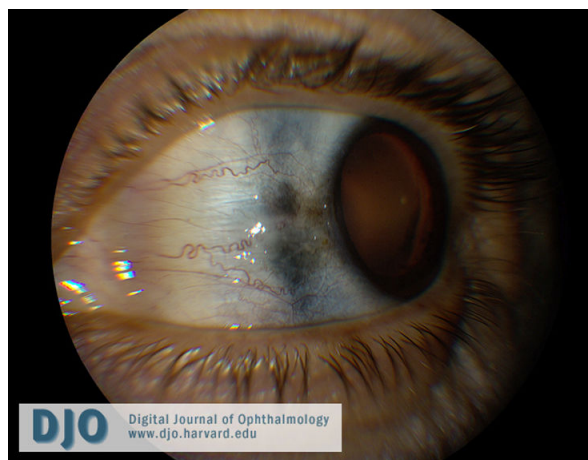

Figure 1. Left eye with bluish-gray scleral hyperpigmentation nasally.

fingerprints were unremarkable. There were no other areas of blue discoloration.

Ancillary Testing

A rheumatologic evaluation revealed no evidence by history or examination of an inflammatory arthritis or other form of systemic autoimmune disease. Rheumatoid factor (RF), antinuclear antibody (ANA), HLA-B27, homocystine acid, ceruloplasmin, and thoracic and lumbar spine films were negative.

Treatment

The patient was counseled to continue cessation of minocycline.

Published May 8, 2010.

Copyright ©2010. All rights reserved.

Reproduction in whole or in part in any form or medium without expressed written permission of the Digital Journal of Ophthalmology is prohibited.

doi:10.5693/djo.03.2010.02.002

Correspondence: Cynthia Chiu, MD, Department of Ophthalmology, University of California, San Francisco, Box 0730, 10 Koret Way, K-125, 94143-0730 (email: ChiuC@vision.ucsf.edu)

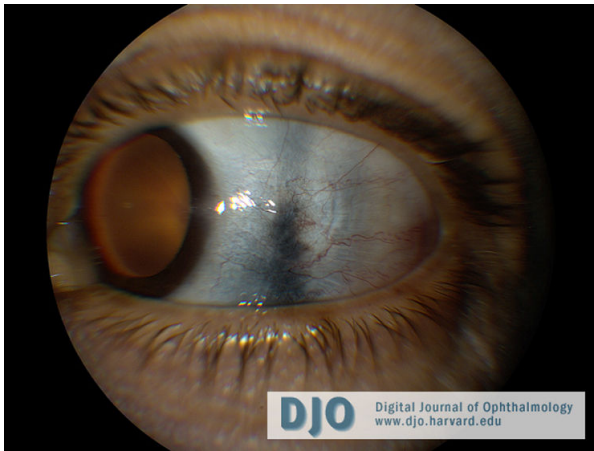


Figure 2. Left eye with bluish-gray scleral hyperpigmentation temporally.

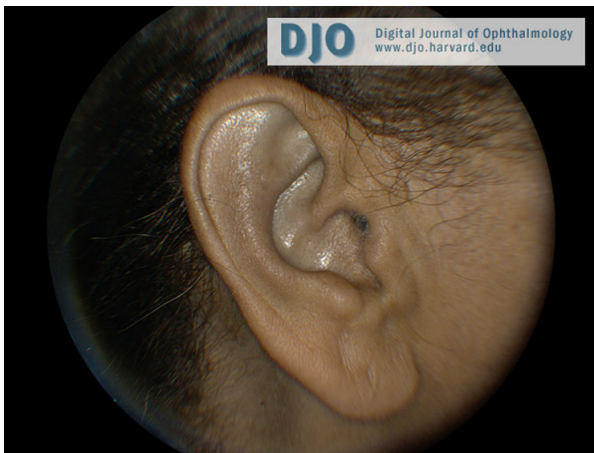

Figure 3. Bluish discoloration of the patient's left ear.

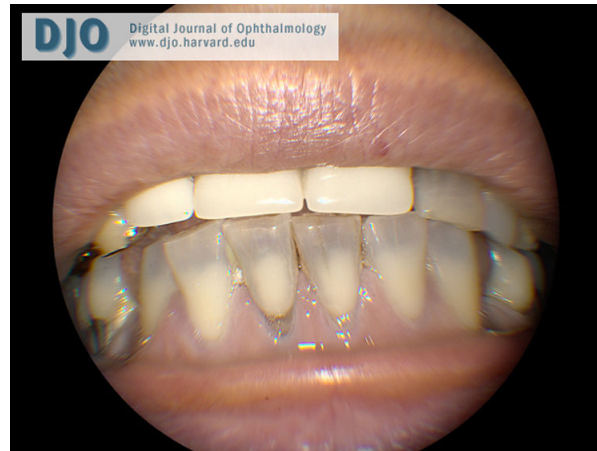

Figure 4. Bluish discoloration of the patient's teeth and gums.

Differential Diagnosis

1. Drug toxicity from prolonged minocycline use was suspected in this patient because she lacked findings suggestive of scleritis, uveitis, vasculitis, or connective tissues diseases and had a history of prolonged, high-dose minocycline use. Other drugs such as nonsteroidal anti-inflammatory medications, amiodarone, cytotoxic drugs (ie, busulfan, cyclophosphamide, bleomycin, adriamycin), chloroquine, phenytoin, antipsychotics (ie, chlorpromazine and related phenothiazines), and heavy metals have been reported to cause scleral hyperpigmentation.¹ However, our patient denied use of these drugs.

2. Scleromalacia is on the differential for sclera hyperpigmentation; however, this patient had no history of autoimmune disease and denied any eye or joint pain. On examination, her sclerae were not thinned and she had no conjunctival injection or uveitis. Rheumatologic work-up was negative for RF and ANA.
3. Choroidal or ciliary body melanomas can cause scleral hyperpigmentation, particularly if they invade through the sclera. Scleral invasion due to choroidal melanoma would be an indication for enucleation; however, retinal examination revealed no choroidal masses in this patient.
4. Addison's disease can cause a bronze hyperpigmentation of the sclera. Our patient denied any weakness, fatigue, anorexia, or abdominal pain.
5. Ochronosis, or skin discoloration due to alkaptonuria, can cause a bluish-black discoloration of the ear and sclera. The patient denied any black discoloration of her urine, as would be expected in alkaptonuria so no further urine testing was performed. Serum homogentisic acid was normal.

Diagnosis

In this patient, there was no sign of scleral thinning to suggest scleromalacia. The posterior segment examination was normal, with no choroidal or ciliary body melanoma. The patient was otherwise healthy, with no systemic symptoms to suggest Addison's disease and no urine discoloration to suggest ochronosis. A diagnosis of profound minocycline-induced scleral pigmentation masquerading as scleromalacia was made. Cutaneous

hyperpigmentation is a known side effect of prolonged high-dose minocycline. Minocycline-induced scleral hyperpigmentation is a diagnosis of exclusion.

Minocycline is a semisynthetic tetracycline used in the treatment of acne vulgaris, rosacea, and as an adjunctive medication for rheumatoid arthritis. It has also been reported to cause hyperpigmentation in the skin,² ears, nails,³ teeth,⁴ bones,⁵ conjunctiva and sclera.^{3,4,6} The scleral hyperpigmentation is often blue-gray, perilimbal, and may be more prominent in sun-exposed areas.^{3,6} In the skin, hyperpigmentation is thought to be due to insoluble complexes of minocycline or minocycline derivatives with iron-related substances or calcium within macrophages of the dermis or epidermis.⁷

Cutaneous hyperpigmentation results from prolonged (greater than 2 years) use of high-dose (greater than 100 mg/day or a total of over 100 g) minocycline.^{3,6} Our patient had taken a total of 1460 grams of minocycline. Skin hyperpigmentation may fade with discontinuation of the drug, particularly if the discoloration is recognized immediately,⁶ but occasionally the hyperpigmentation may be permanent.⁴ Cutaneous hyperpigmentation is an indication for discontinuing minocycline.^{4,6} Our patient had coincidentally stopped minocycline use 2 years prior to presentation but continued to have persistent and stable scleral, ear, and gingival hyperpigmentation, suggesting that her hyperpigmentation is permanent.

Patients with minocycline-induced scleral hyperpigmentation present with a painless, blue scleral discoloration.

These patients are otherwise healthy, with no other signs of systemic disease. Since this is a diagnosis of exclusion, all other causes of scleral hyperpigmentation must be considered and excluded. Scleral hyperpigmentation due to minocycline is treated with medication cessation. However, some cases of very prolonged high-dose minocycline use, as in our patient, may have permanent and irreversible pigment changes. Recognition of minocycline toxicity as a cause of scleral hyperpigmentation is key in preventing a patient from receiving systemic immunosuppression, particularly when other signs of scleromalacia are absent.

References

1. Dereure O. Drug-induced skin pigmentation. Epidemiology, diagnosis and treatment. *Am J Clin Dermatol* 2001;2(4):253-62.
2. McGrae JD Jr, Zelickson AS. Skin pigmentation secondary to minocycline therapy. *Arch Dermatol* 1980;116(11):1262-5.
3. Wolfe ID, Reichmister J. Minocycline hyperpigmentation: skin, tooth, nail, and bone involvement. *Cutis: cutaneous medicine for the practitioner* 1984;33(5):457-8.
4. Morrow GL, Abbott RL. Minocycline-induced scleral, dental, and dermal pigmentation. *Am J Ophthalmol* 1998;125(3):396-7.
5. Rumbak MJ, Pitcock JA, Palmieri GM, Robertson JT. Black bones following long-term minocycline treatment. *Arch Pathol Lab Med* 1991;115(9):939-41.
6. Fraunfelder FT, Randall JA. Minocycline-induced scleral pigmentation. *Ophthalmology* 1997;104(6):936-8.
7. Fenske NA, Millns JL. Cutaneous pigmentation due to minocycline hydrochloride. *J Am Acad Dermatol* 1980;3(3):308-10.